IBRA International Bone Research Association

FLASH 2023

Editor's Message

Welcome to our new Flash 2023. In this year's issue, we proudly present our achievements, initiatives, and collaborations, which together embody the spirit and will of our members regarding the further expansion of our association, as well as the progress and excellence in our offerings in continuing medical education and research.

The careful and steadfast implementation of strategic guidelines, which accompany and guide us in expanding our high-quality services and undertakings on a global scale, is central to our efforts and activities.

In this regard, the focus is on maintaining our worldwide connections and contacts—both scientific and interpersonal—in international medical education. The exchange of ideas, research findings, and experiences not only drives our understanding of educational needs, but also fosters a sense of camaraderie that transcends boundaries.

The growth of activities at our headquarters and around the world reflects our unwavering commitment, which we have pursued for many years from "head to toe", and continue to expand. In this regard, the findings of a recent survey of our members conducted by IBRA are extremely valuable. The resounding interest expressed, especially by young physicians, in hands-on training and education demonstrates an important way forward. Our continued efforts and initiatives are essential in preparing both our young physicians and ourselves to excel.

With this in mind, we achieved a major milestone with the inauguration of our own Bioskills Laboratory at our headquarters in Basel. This state-of-the-art facility is a testament to our commitment to hands-on learning and skills development, where knowledge is put into practice and where theory and technology merge seamlessly.

Together, we will continue to shape the future of medical education through strategic implementation, international expansion, scholarly engagement, and cultivating friendships across borders.

Thank you for joining us on this remarkable journey.

The IBRA Administration Team

© 10/2023 - IBRA, Basel, Switzerland

TABLE OF CONTENTS

IBRA – General Information

Editor's Message, Table of Contents	2–3
IBRA North America Thrives in 2023: A Year of Achievements and Advancements	4
Pioneering Excellence in Hand Surgery Education: Interview with Dr. Duretti Fufa, New York, United States	5
IBRA Institute Opens in Basel – An Innovative Hub for Training, Medical Education, and Research	6–9
Meet our IBRA Training Centers	10–11
Overview of IBRA's Extensive Global Network of Training Centers	12–13
IBRA Survey Reveals Member Insights	14
Report from IBRA's Research and Education Committees (RECs)	15
Scientific Collaboration between Japan and Europe: Short Report on the IBRA Traveling Fellowship Program	16–18
IBRA Report	19–20
New Application Process for Full Membership	21
IBRA 2024 Curriculum	22–22
Empowering Members through Information and Connection	24–25

Technical Reports

Lower Limbs

26–29 A Case Report of Charcot-Marie-Tooth Disease with Atypical Progressive Collapsing Foot Deformity (PCFD)
Simone Santini, Victor Valderrabano, Mario Herrera-Pérez

Upper Limbs

30–34 Guyon's Canal Syndrome – An Unusual Cause
Alejo Garcia Bensi, Pablo López-Osornio, Joaquin Casañas

35–37 Revision Nonunion ORIF for Scaphoid Waist Fracture with a Volar Carpal Artery Vascularized Graft
Michelle Zeidan

38–41 Good Clinical Outcome after Operative Therapy of an Anterior Facet Fracture of the Coronoid Process: A Case Report
Sebastian Wegmann, Tim Leschinger, Lars Peter Müller, Michael Hackl

Head

42–45 Frontal Sinus Fractures: Clinical Considerations and Surgical Approaches to Reconstruction
Raphael Capelli Guerra, Henrique Cabrini Moreira, Henry Guevara García, Eduardo Hochuli Vieira, Andreas Neff, Philipp Jürgens, Bianca de Fátima Borim Pulino

46–49 Orthognathic Surgery in Hypodontia and Edentulous Patients
Johannes Kleinheinz, Susanne Jung, Claudius Middelberg, Thomas Stamm

Case Presentation

Head

50–51 Importance of Malocclusions in Rare Diseases and Malformations Affecting the Cranio-Maxillofacial Area
Joël Ferri

IBRA North America Thrives in 2023: A Year of Achievements and Advancements

IBRA's North America Chapter has once again proven its dedication to advancing the field of orthopedic surgery for upper and lower limbs. Throughout the year, IBRA North America has orchestrated an array of events and initiatives that have garnered significant attention and appreciation within the medical community. With a steadfast focus on promoting the latest surgical techniques, fostering international relationships, and providing educational opportunities, the Chapter's efforts have made an impact on both a local and global scale.

One of the most notable achievements of IBRA North America in 2023 has been the successful launch of six IBRA courses held across the United States. These courses have become pivotal gatherings for surgeons specializing in upper and lower limbs, enabling them to exchange insights, learn from experts, and gain hands-on experience in the latest surgical techniques. Four courses explored upper limbs, while the other two courses focused on lower limbs.

In line with its dedication to education, IBRA North America has continued to expand its training infrastructure: for lower limbs, the Duke Department of Orthopaedic Surgery in Durham and the Carver College of Medicine of the University of Iowa now stand as beacons of excellence, providing surgeons with unparalleled training opportunities. Meanwhile, for those specializing in upper limbs, the Badia Hand to Shoulder Center in Miami and the Banner University Medical Center at the University of Arizona in Phoenix offer comprehensive training programs that encompass the latest advances in the field.

IBRA's global reach has been further strengthened by the Chapter's commitment to its scholarship program. Four talented surgeons from the United States were given the opportunity to take part in the IBRA scholarship program, allowing them to broaden their horizons and refine their skills by visiting hospitals in Italy and Australia.

Inter-American cooperation has also been intensified by three surgeons from the United States taking a key role in IBRA activities at the 43rd Brazilian Congress of Hand Surgery. These initiatives embody the association's ethos of fostering international collaboration and enriching the experiences of its members.

IBRA North America also played an active role in the American Society for Surgery of the Hand (ASSH) Congress this year. A highlight of this was the establishment of a surgical suite, emphasizing the Chapter's dedication to facilitating hands-on learning and knowledge exchange. Such efforts contribute not only to the advancement of surgical techniques but also to the enrichment of the wider medical community.

In conclusion, IBRA North America's achievements in 2023 serve as a testament to the organization's unwavering commitment to excellence and progress in orthopedic surgery. Through a combination of cutting-edge educational initiatives, international collaboration, and active engagement at prestigious events, IBRA North America continues to push boundaries and break new ground.

Pioneering Excellence in Hand Surgery Education

Interview with Dr. Duretti Fufa, Hospital for Special Surgery, New York, US.
Member of the IBRA Research and Education Committee Upper Limbs North America

In the realm of hand surgery, expertise isn't just cultivated in the operating room—it's fostered through a unique blend of innovation, collaboration, and continuous learning. At the forefront of this dynamic field stands Dr. Duretti Fufa, an eminent hand surgeon whose contributions have left an indelible mark on the art and science of surgical education. With a rich history of collaboration with IBRA Dr. Fufa's impact extends far beyond her surgical prowess, encompassing a transformative role in shaping the future of hand surgery education.

What differentiates IBRA advanced courses from other courses available?
The appropriate balance between didactics, lectures, talks, and hands on activity is really tough to strike. We know that as adult learners it is important to have limited time where we are just sitting and listening. So, participants always enjoy the hands on aspects, the interactive aspects, of discussing cases, being in the lab, getting to use your hands as part of these courses. Hence, I think this is something that all of us strive to incorporate to optimize learning for adults.

How important is international scientific collaboration?
Especially after the couple of years that we have had, the ability to interact with colleagues from around the world is just so valuable. We are very fortunate to have a lot of advances that come from the United States but we always learn more by broadening our perspectives, and we can learn a lot, especially in the domain of Osteosynthesis, from our colleagues in Europe. So it is a tremendous pleasure to be able to have this level of collaboration.

What are the benefits of using pre-fractured specimens with realistic fracture patters in medical education?
In a surgical simulation, which is what all of these training courses are doing, we are attempting to make surgery as realistic as possible. It goes from lower fidelity type models, called sawbones, to the ability to utilize anatomical specimens, which is such a privilege to have. Traditionally, even when we have the benefit of using an anatomical specimen, we are just putting a plate and screws on an intact bone. To have injured wrists and other body parts is therefore a tremendous advantage in terms of making this more proximate to what we are really doing in surgery. The other huge advantage is that when the specimens are pre-fractured, we start as a group by looking at the X-rays. This much more closely simulates what we do in cases, where we look at the X-rays and start to decide, do we want to use a dorsal approach for this? Do we want to use a volar approach? What instrumentation may we decide to choose? So, it really just brings us a lot more close to the real life situation. And obviously what that does, is allow the participants to have even better preparation when they walk into the operating room.

Who do you think will find IBRA advanced courses beneficial?
I think that these courses can appeal to such a broad range of trainees, as well as faculty. I have enjoyed participating in IBRA courses so much not only because of the hands-on training that we get, but also the interaction with colleagues that may be other residents who are interested in hand surgery. It might be with faculty members who you may seek out as mentor one day or who you may be able to seek out for job opportunities. And then on the faculty side, you get to really interact with colleagues again from other institutions, with other practices and learn a lot from them. So, I think all the way from the sort of earlier trainee who is differentiated towards being a hand surgeon, there is a tremendous amount to learn about: to learn from the practical aspects, the networking aspects, but also on the already practicing surgeon side, the ability to keep up your understanding of the ways that people are doing things in different parts of the country. Then, from the faculty side, like I mentioned, getting to pick the brains of these other amazing surgeons is fantastic. So, there is almost an unlimited spectrum of people that these courses would be appealing to in my opinion.

What has been your personal experience with IBRA?
I had the opportunity to attend an IBRA course when I was a senior resident. This really opened my eyes to what is so special about this courses. It is a very intimate environment with renowned faculty from around the country and around the world. Having exposure to just sitting and hearing them talk about their approaches and speak with each other about it was wonderful. This is just aside from the opportunity to practice in these state-of-the-art simulation kind of labs. To then be able to transition to a faculty member is a real honor. To see the other side of has been wonderful: the preparation for the courses, the preparation of our syllabus and also working together to bring hopefully the best content for the participants.

→ www.ibra.net

IBRA Institute

BioSkills by IBRA International Bone Research Association

IBRA Institute Opens in Basel – An Innovative Hub for Training, Medical Education, and Research

A new hub for practical training, education, and the development of new surgical techniques in the heart of Europe. On August 24, 2023, another very important chapter was added to IBRA's history. The long-awaited IBRA Institute at the IBRA headquarters in Basel was officially inaugurated. This step marks a significant milestone that stands for our commitment to excellence in medical education and research.

Just one week later, the first surgeons were able to inaugurate the new facilities for the IBRA Advanced Course on "Orbital, Condylar and Coronal Approaches - Internal Fixation." It was a pleasure to work in the spacious, modern, and light rooms that are equipped with the latest technology.

It is no coincidence that the first course in the new IBRA Institute premises also represents the very first IBRA segment, cranio-maxillofacial surgery, which marked the beginning of IBRA almost 20 years ago.

→ www.ibra.net

INTERVIEW

José Manuel Vázquez
Executive Director
IBRA International Bone Research Association
Hochbergerstrasse 60E
CH-4057 Basel



Ricardo Novo
Laboratory Manager
IBRA Institute
Hochbergerstrasse 60E
CH-4057 Basel

In an interview with José Manuel Vázquez, IBRA's Executive Director, and Ricardo Novo, Laboratory Manager, we learn why the new IBRA Institute is so important and what services it can provide to scientists and healthcare professionals.

José Manuel, what goals is IBRA pursuing with its new bioskills lab?

In a constantly evolving environment, it is important to respond quickly to specific needs and to be agile in meeting the growing global demand for dedicated continuing education.

A recent survey conducted by IBRA, to which over 700 IBRA members responded, clearly demonstrates the importance and need for practical training. We have been doing this for years by offering dedicated and specialized scientific courses around the world. So for me, our own training facilities in Basel is the logical next step in developing our courses and expanding their content. Finally, the new training facility will allow access to anatomical workshops for countries where access is difficult or not permitted.

In addition, we want to offer our members, course participants, and clients a realistic surgical environment for their training and exchange of experiences by providing new technologies and complete surgical equipment, such as the latest implant systems, CT scanners, fluoroscopes, power tools, and endoscopic and arthroscopic systems.

It is important to keep logistics as simple as possible, or even better, to have the equipment already installed and ready to use for both smaller local groups and larger international seminars and workshops.

Ricardo, what opportunities does the IBRA Institute offer?

The IBRA Institute provides a realistic environment where medical professionals and students alike can deepen their understanding of human anatomy and physiology and improve their practical skills by examining and working on human specimens.

With a total area of 870 m^2, the anatomy lab will include wet/dry labs, two X-ray rooms with radiolucent surgical stations, a CT room, a prep area, a wash and sterilization room, production and R&D facilities, a freezer and cold storage room, a film studio for recordings and live broadcasts, a catering area, IBRA administrative offices, and an exhibition and booth area. Services will be tailored and scaled according to the objectives and needs of each client.

We focused on the following key areas of use when designing the lab:

- **Education and Training:**
  Having our own bioskills laboratory allows us to train and educate medical professionals and students under our own conditions and within an infrastructure that meets the highest ethical standards. Bioskills labs provide hands-on learning experiences that allow individuals to develop their anatomical knowledge and surgical skills for the benefit of patients.

- **Research and Development:**
  Human tissue labs are also essential for medical research and development. By studying anatomical structures and functions, researchers can gain valuable insights into diseases and medical conditions, leading to the development of new treatments and therapies.

In addition, we will establish our own fracture simulator in Basel, developed in collaboration with the University of Cologne, and continue to create procedures using new patented technologies.

This will allow us to improve logistics and keep distances as short as possible for providing specimens, and also allow us to accompany and support our own research projects, leading to a better understanding of fractures and their treatment.

- **Design and Testing of Medical Devices:**
  Bioskills labs can also be used for the design and testing of medical devices, which will add significant value to the development and make-up of new implants. By testing these devices on human specimens, designers can ensure that they are safe and effective for use in medical procedures.

- **Continuing Education:**
  For practicing medical professionals, bioskills labs can be a valuable resource for continuing education and professional development. Physicians, surgeons, and other medical professionals can use anatomy labs to refresh their knowledge of anatomy and practice surgical procedures.

- **Innovation:**
  Finally, biomedical training facilities can be a place of innovation and experimentation. By exploring new techniques and technologies, medical professionals can push the boundaries of what is possible in the medical field and develop new approaches to treating diseases and conditions.

In conclusion, a new bioskills lab can serve many purposes, from education and training to research and development, medical device design and testing, continuing education, and innovation. Whatever the reason for establishing an anatomy lab, it is important to ensure that it is run ethically and with respect for the donors whose bodies are used for medical education and research.

→ www.institute.ibra.net

CLIMBA - Hand Clinic Buenos Aires, Argentina

Dr. Aldo Enrique Falco
Viamonte 1632 (1055)
1055 Ciudad Autónomo de Buenos Aires
Argentina
Phone/Fax: +5411 5252 6266
info@climba.com.ar

¡BIENVENIDO!

My colleagues and I are looking forward to welcoming fellows to our facility, sharing knowledge in our field, as well as culture and diversity. We are a group of five board-certified upper limb specialists, trained in different centers, and enjoy teaching and learning from our colleagues. We also have an annual fellowship, and many other hand surgeons working with us, which gives international guests numerous opportunities to share knowledge and experiences.

INTRODUCTION OF EXPERTISE

We specialize in hand and wrist trauma, wrist, elbow, and shoulder arthroscopy, rheumatic pathology, and sports injuries. As an outpatient facility in Buenos Aires, Argentina, we have two operating rooms and perform approximately 2,600 surgical procedures and 25,000 consultations every year. Our location in the capital city provides a unique cultural experience, blending South American flair with European elegance. Buenos Aires offers a wide range of cultural activities and exquisite cuisine, from traditional "Asado" to international dishes influenced by various regions. It is a friendly city with a great public transport network and a vast selection of accommodation options.

DAY-TO-DAY SHADOWING

Climba opens its doors at 7 a.m. every day. We carry out surgical procedures and clinics throughout the day. Fellows are free to observe surgeries and clinics, but we strongly encourage them to "follow" a patient, so they can see the rationale behind the diagnosis, surgery, and postoperative care. We also work closely with the rehabilitation service, and fellows are able to discuss postoperative rehabilitation options.

In Climba, fellows are encouraged to participate in all scientific activities. We have case presentations with discussions supported by literature every week, and there is a monthly multicenter discussion panel, where other fellowship programs present cases, followed by complex discussions. Fellows are also welcome to present their own cases for opinions and feedback.

Universitätsklinikum Köln - Klinik und Poliklinik für Orthopädie und Unfallchirurgie, Cologne, Germany

Univ.-Prof. Dr. Lars P. Müller
Kerpener Strasse 62
50937 Cologne
Germany
Phone: +49 221 478 4802
Fax: +49 221 478 4835
unfallchirurgie@uk-koeln.de

WILLKOMMEN!

Trauma and orthopedic surgery of the upper limbs is an exciting aspect of our field. We focus on advanced hand, shoulder, and elbow surgery, alongside covering general trauma surgery in a vibrant city of one million inhabitants. Fellows will fully integrate into our clinical routine and work with staff members who are open to new ideas, giving them the opportunity to enhance surgical profiles and expand scientific horizons. They can experience the clinical expertise of a Level 1 Trauma Center renowned for upper limb surgery. Our team is innovative, inquisitive, and open to international exchange. We look forward to welcoming fellows to Cologne.

INTRODUCTION OF EXPERTISE

Our clinic performs frequent upper limb surgical procedures for various indications, including fractures, ruptures, instabilities, and deformities. We cover general and specialized trauma for upper and lower limb injuries, pelvis, and spine, using minimally invasive and arthroscopic techniques to achieve optimal clinical outcomes. The clinic's main focus is on upper limb surgery, starting with the shoulder, down to the elbow and hand.

DAY-TO-DAY SHADOWING

Our day starts with a morning briefing at 7.30 a.m. Fellows get to visit the operating rooms and can actively assist in daily surgeries. We offer special consultations for each anatomical region and fellows are welcome to present their own cases to brainstorm together and develop new ideas. We offer numerous opportunities for further interaction in our clinic and weekly training sessions, as well as an extremely well-equipped biomechanics lab, facilitating the development of scientific ideas in our creative environment.

Galeazzi-Sant'Ambrogio Hospital - Hand Surgery Unit, Milan, Italy

Dr. Alberto Lazzerini
Galeazzi-Sant'Ambrogio Hospital
Via Cristina Belgioioso 173
20157 Milano
Italy
Phone: +39 02 83500010
info@drlazzerini.com

BENVENUTI!

Our team is always available to answer any questions and discuss cases with fellows. Milan is an attractive city with an intense social and cultural life. It is close to the mountains, lakes, sea, and some of the most famous tourist destinations in Italy. The city also offers numerous exciting professional and educational opportunities with a young, international community. Affordable short-term rentals and shared apartments are readily available.

INTRODUCTION OF EXPERTISE

The Hand Surgery Unit at Galeazzi-Sant'Ambrogio Hospital in Milan is a modern and friendly facility that covers all aspects of hand and wrist surgery, including both trauma and elective cases. The unit has four surgeons and two residents, and performs approximately 1,500 surgical procedures every year.

DAY-TO-DAY SHADOWING

Outpatient clinics are held every day from Monday to Friday, with working hours from 8.00 a.m. to 7.30 p.m. Fellows can take part in all clinical activities, including surgery and outpatient clinics, and are encouraged to participate in case discussions and staff meetings.

Research fellows staying for three months or more can initiate research with the team, with protocols being carried out by members in various fields of hand surgery, while project design before the visit is possible for ethical committee evaluation and approval, and continuing cooperation can be arranged after the visit, with encouraged participation in case discussions and staff meetings.

University Hospital of the Canary Islands, La Laguna, Spain

Prof. Dr. Mario Herrera-Pérez
Carretera de La Cuesta s/n
38320 La Laguna, Tenerife
Canary Islands
Spain
Phone: +0034 922678500
herrera42@gmail.com

¡BIENVENIDO!

Senior residents and foot and ankle specialists interested in intensive rotation programs are welcome at our IBRA Training Center. We offer a unique people-centered and scientific environment in a functional foot and ankle unit at the forefront of Europe.

INTRODUCTION OF EXPERTISE

Our Foot and Ankle Unit at the University Hospital of the Canary Islands is a prestigious center specializing in advanced surgery of foot and ankle disorders. We cover a wide range of reconstructive foot and ankle surgical procedures, including complex trauma, foot and ankle arthroscopy, prosthetic surgery, and percutaneous surgery. This unit, which is part of a third-level teaching hospital attached to the University of La Laguna, serves a potential population of 400,000 inhabitants. This unit is integrated with the traumatology and orthopedic service with 30 consultants and five residents.

We provide patients with tailored treatment for post-traumatic, congenital, and acquired deformities in the foot and ankle that are based on the latest research findings and literature. Due to the nature of our center, we receive a high volume of trauma patients through our doors, so one of our key areas is foot and ankle trauma and also post-traumatic conditions (osteotomies, arthrodiastasis, arthrodesis, etc.). Our expertise also covers hindfoot, midfoot, and forefoot arthritis, as well as deformities, such as planovalgus, cavus foot, bunions, and hammer toe.

DAY-TO-DAY SHADOWING

We take an active role in research and fellows are encouraged to become involved in ongoing scientific studies. Our program includes performing surgeries as an assistant, participating in daily activities, and assisting the three members of the unit. We have up to three operating rooms every week and one day of outpatient consultations.

An extensive global network of training centers provides an interesting range of options for scholarship applicants

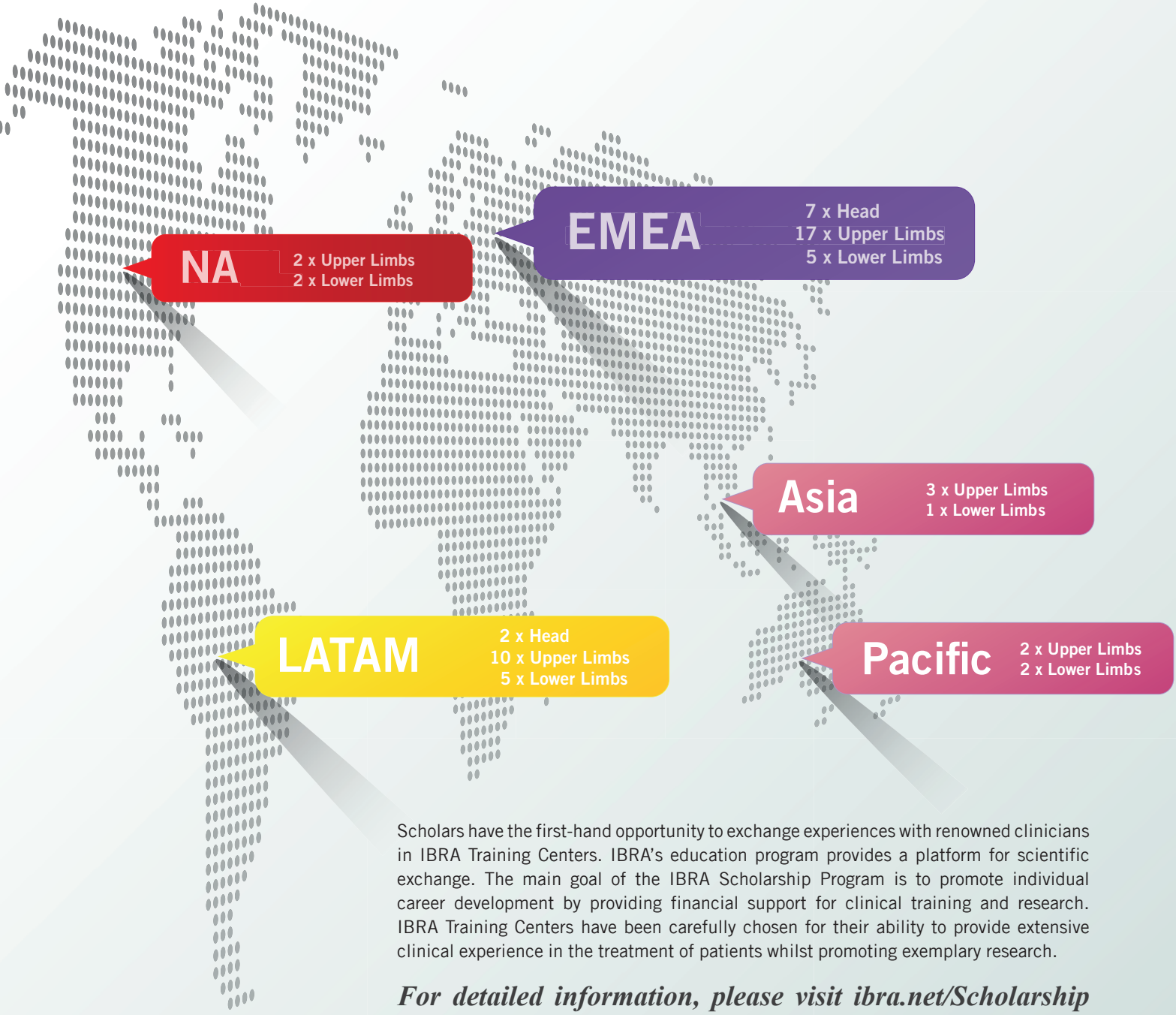

Scholars have the first-hand opportunity to exchange experiences with renowned clinicians in IBRA Training Centers. IBRA's education program provides a platform for scientific exchange. The main goal of the IBRA Scholarship Program is to promote individual career development by providing financial support for clinical training and research. IBRA Training Centers have been carefully chosen for their ability to provide extensive clinical experience in the treatment of patients whilst promoting exemplary research.

For detailed information, please visit ibra.net/Scholarship

Upper Limbs

Argentina
- Hospital Italiano, Buenos Aires
- Climba, Buenos Aires

Australia
- John Hunter Hospital, Newcastle
- Dandenong Hospital, Melbourne

Austria
- Unfallkrankenhaus Lorenz Böhler, Vienna
- Medical University of Innsbruck

Brazil
- Instituto Nacional de Traumatologia e Ortopedia, Rio de Janeiro
- Beneficência Portuguesa Hospital, São Paulo
- University of São Paulo, School of Medicine
- Hospital Israelita Albert Einstein, São Paulo
- Instituto Vita, Department of Hand & Wrist Surgery and Micro-surgery, Department of Shoulder & Elbow Surgery, São Paulo
- Rede Mater Dei de Saúde Orthopedics, Trauma & Hand Surgery, Belo Horizonte

Chile
- Clínica Santa María, Santiago

Colombia
- Medellín Health Centers, Medellín

Czech Republic
- Klinika Dr. Pírka, Mladá Boleslav

Germany
- St. Elisabeth Hospital, Ravensburg
- University Hospital Cologne
- University of Würzburg
- Klinikum rechts der Isar, Munich

Italy
- Policlinico of Modena
- Policlinico GB Rossi, University Hospital Verona
- Galeazzi Hospital, Hand Surgery Unit, Milan
- Azienda Ospedaliero-Universitaria Careggi (AOUC), Department of Hand Surgery and Reconstructive Microsurgery, Florence

Netherlands
- Maastricht University Medical Center

Singapore
- Singapore General Hospital (SGH), Hand & Reconstructive Microsurgery

South Korea
- Seoul National University Bundang Hospital
- Korea University Anam Hospital, Seoul

Spain
- Centro Medico Teknon, Barcelona
- University Hospital of Santiago, Santiago de Compostela

Switzerland
- Kantonsspital St. Gallen

United Kingdom
- Wrightington Hospital, Wigan
- Guy's and St Thomas' NHS Foundation Trust, London

USA
- Badia Hand to Shoulder Center, Miami
- Banner University Medical Center at the University of Arizona-Phoenix

Lower Limbs

Argentina
- Austral University Hospital, Orthopedic and Traumatology Department, Buenos Aires

Australia
- John Hunter Hospital, Newcastle
- Nepean Hospital, Orthopedic, Kingswood

Brazil
- Paulista School of Medicine - Federal University of São Paulo
- Hospital Israelita Albert Einstein, São Paulo
- Instituto Vita, Department of Foot & Ankle Surgery, São Paulo

Chile
- Clínica Santa María, Santiago

Germany
- Medical School at Diakovere Annastift, Hannover

Japan
- Laketown Orthopedic Hospital, Koshigaya

Spain
- University Hospital of the Canary Islands, Tenerife

Switzerland
- Swiss Ortho Center, Basel

United Kingdom
- Trauma and Orthopedic Department of the North West Anglia NHS Foundation Trust, Peterborough
- Guy's and St Thomas' NHS Foundation Trust Department of Orthopaedics, London

USA
- University of Iowa, Carver College of Medicine, Department of Orthopedics and Rehabilitation, Foot and Ankle Division, Iowa City
- Duke University - Department of Orthopaedic Surgery Durham, North Carolina

Head

Brazil
- São Paulo State University
- Hospital Samaritano, Higienópolis, São Paulo

France
- University of Amiens
- University of Lille

Germany
- University of Münster
- University Hospital of Giessen and Marburg

Italy
- Sapienza Università di Roma

Switzerland
- Inselspital University Hospital of Bern

United Kingdom
- Sheffield Teaching Hospitals

→ www.ibra.net/Training-Centers

IBRA Survey Reveals Member Insights: Tailoring Education and Training to Meet Demand

In Spring 2023, IBRA conducted a comprehensive survey among its members to gain deeper insight into their educational needs and preferences regarding in-person versus virtual events. 2,500 individuals were contacted and 720 kindly completed the questionnaire. The results of the survey provide valuable information that will help IBRA enhance its training opportunities and align them more closely with the demands of its diverse member base.

Education Needs in Focus

One of the primary objectives of the survey was to identify the key areas of interest in education among IBRA members. The results show that trauma and reconstruction are the most sought-after topics, followed closely by osteosynthesis.

Training Needs: Practical Exposure and Surgical Skills

When asked about their primary training needs, members emphasize the importance of practical exposure, be it with human or animal specimens. The opportunity to gain hands-on experience and develop surgical skills is highlighted as a high priority for IBRA members. These findings indicate a strong emphasis on providing training that equips members with tangible, applicable skills for their professional development.

In-person vs. Virtual Learning Preferences

The survey delved into members' preferences regarding in-person versus virtual learning. In-person training is the overwhelming preference, with members valuing the benefits of face-to-face interactions and immersive learning experiences. This preference is particularly evident when it comes to instructional/practical courses with human or animal specimens.

Webinars: The Preferred Online Learning Method

For online learning, webinars are the preferred format, offering flexibility while retaining a sense of real-time engagement. The dynamic nature of webinars allows for interactive learning and fosters a strong sense of community among members.

Online Self-Study: Web-Based Learning Preferred

When it comes to self-study online learning, web-based platforms are favored over app-based learning and community learning. The convenience and accessibility of web-based resources provide IBRA members with the freedom to learn at their own pace while accessing valuable educational materials.

Perceived Effectiveness: In-Person Training Takes the Lead

The survey findings demonstrate that in-person training is generally perceived as more effective than virtual learning. Members highlight the importance of hands-on practice and real-time feedback, as well as interaction with experts in the field, which are best facilitated in on-site settings.

Importance of CME Certification

Opinions among members are divided when it comes to the importance of Continuing Medical Education (CME) certification. Just over one-third of respondents consider international accreditation, such as ACCME/EACCME, to be important. A slightly smaller proportion found national accreditation to be crucial, while approximately 30% did not see it as a top priority.

Strengthening Educational Opportunities

The results from this survey already show a solid alignment between IBRA's current educational offerings and the needs articulated by its member base. The findings will now be leveraged by IBRA's Research and Education Committees, in conjunction with the IBRA Administration Office, to tailor training opportunities even further.

In conclusion, IBRA would sincerely like to thank all members who took part in the survey. Your insights and opinions are the driving force behind the association's continuous growth and progress.

Report from IBRA's Research and Education Committees (RECs): CMF/Head, Upper and Lower limbs

International Bone Research Association's (IBRA) Research and Education Committees CMF, Upper and Lower Limbs convened virtually in March 2023, marking another significant step in advancing bone research and education.

The meetings brought together esteemed members of the committees:

CMF/Head:
Prof. Dr. Dr. Philipp Jürgens, Prof. Dr. Dr. Christian Freudlsperger, Prof. Dr. Dr. Benoit Schaller, Dr. Dr. Timothy Lloyd, Mr. Claudio Darms as industry representative, and Prof. Dr. Dr. Andreas Neff as guest.

Upper Limbs:
Dr. Christoph Pezzei , Prof. Dr. Rames Mattar Jr., and Matthias Walter as industry representative. The members of the committee Prof. Dr. Adam Watts and Prof. Dr. Kilian Wegmann were unfortunately unable to attend this meeting.

Lower Limbs:
Prof. Dr. Dr. Victor Valderrabano, PD Dr. Christian Plaass, and Prof. Dr. Mario Herrera and Mr. Thiago Goncalves as industry representative.

The meetings were supported by the IBRA Administration Team: Mr. José Manuel Vázquez (IBRA Executive Director), Ms. Caroline Tschanz (IBRA Assistant), PhD Tobias Hövekamp (Global Lead Scientific Education CMF/Head), Ms. Katharina Roth (Global Lead Scientific Education Extremities).

The REC meetings served as a platform to unveil a range of upcoming educational events and courses scheduled for the second half of 2023. During the meeting, various details and logistics were finalized to ensure their successful execution. These events will provide a valuable opportunity for researchers, practitioners, and industry professionals to enhance their understanding and expertise in the field of bone research.

Furthermore, the committees delved into the discussion of the 2024 itinerary for educational events and courses. Building upon the foundation laid in 2023, the proposed plan for the upcoming year aims to offer a diverse range of educational opportunities, catering to the evolving needs and interests of the bone research community.

In line with IBRA's commitment to nurture young talent, considerable attention was paid to the scholarship program during the meeting. The program continues to attract numerous applications from aspiring individuals who are eager to broaden their knowledge, skills, and horizons in the field. After careful evaluation, 32 exceptional applicants were selected to participate in the 2023 program, which provides them with the opportunity to train at renowned international centers of excellence. This initiative not only promotes academic growth but also facilitates the exchange of ideas and collaboration among emerging researchers.

Lastly, the REC meetings initiated long-term planning discussions for future events beyond 2024, emphasizing IBRA's dedication to sustained progress in the field of bone research. This forward-looking approach ensures that the association remains at the forefront of cutting-edge developments, enabling it to address critical challenges and drive innovation.

As the meeting concluded, the commitment to conduct significant research stood out as a core pillar of IBRA's mission. By setting a clear direction for the future, the RECs reaffirmed the association's dedication to pushing the boundaries of knowledge and improving the lives of individuals affected by bone-related conditions.

Subsequent REC meetings will build upon the initiatives undertaken and focus on the long-term planning for events in 2025 and beyond. IBRA's unwavering commitment to research and education continues to pave the way for transformative breakthroughs and a brighter future in the realm of bone research.

Scientific Collaboration between Japan and Europe

International scientific networking is a primary global goal and a key attribute of IBRA, and we strive to uphold this in all our educational events, activities, and services. By doing so, IBRA actively supports and promotes the exchange of knowledge, research, and progress within our fields and, with special interest, in our collaborations with IBRA Training Centers.

With a focus on fostering engaged collaboration across geographic and cultural borders with our IBRA Members and Training Centers, we initiated a Lower Limb Traveling Fellowship, serving as a pilot project between Japan and Europe.

In close collaboration and agreement with our Japanese IBRA Premium Members and the IBRA Research and Education Committee (REC) for Lower Limbs, Dr. Hiromu Ito MD. PhD. and Dr. Masato Ogawa, MD. PhD. were selected as the most suitable candidates.

In November 2022, they embarked on their journey, visiting some of our European IBRA Lower Limbs Training Centers and participating in the IBRA Master Course "Contemporary Challenges and Perspectives in Foot & Ankle Surgery" in Basel.

Short Report on the IBRA Traveling Fellowship Program

Dr. Hiromu Ito and Dr. Masato Ogawa, November 7–21, 2022

First of all, we would like to thank IBRA, as well as the outstanding Research and Education Committee for Lower Limbs and fellowship directors, for giving us this opportunity to take part in the very first Japan-Europe Foot and Ankle IBRA Traveling Fellowship Program. This program was founded in 2020, but unfortunately had to be postponed because of the COVID-19 pandemic. However, as the world started to emerge from the pandemic, we were extremely happy when IBRA decided to launch the program last year.

We first flew from Haneda International Airport in Tokyo to Hanover and visited Prof. Dr. med. Christina Stukenborg-Colsman and PD Dr. med. Christian Plaass in Hanover Medical School at Diakovere Annastift in Germany on November 8, 2022. We were shown an array of remarkable and meticulously-executed surgical procedures, encompassing treatments for Hallux valgus, flat foot, and OCD of the talus. The extent of expertise was clearly evident as these intricate operations were skillfully demonstrated.

Furthermore, Dr. Plaass thoughtfully organized a captivating city tour, where we learned an incredible amount about the history of Hanover.

We then moved to Peterborough City Hospital of North West Anglia NHS Foundation Trust, Peterborough in England on November 10, and visited Dr. Jim Carmichael and Dr. Ravindra Kamath. This IBRA Training Center stands as a prominent orthopedic facility in the region, treating a high volume of patients with traumatic and chronic foot diseases. During the visit, the team shared insights into an exclusive subset of their unique trauma and osteoarthritic surgeries, exemplifying the hospital's exceptional expertise.

Our next destination was Tenerife, part of the Canary Islands, which is one of the most beautiful islands in the whole of Europe. Prof. Dr. Mario Herrera met us at the airport and took us to the city of Santa Cruz de Tenerife. Our visit coincided with a festival, giving us the wonderful opportunity to immerse ourselves in the local customs and traditions. We visited the University Hospital of the Canary Islands on November 14, and Prof. Dr. Mario Herrera provided a comprehensive demonstration of numerous remarkable surgical procedures, including ligament reconstruction and lateral column lengthening. Subsequently, a wide range of case-related subjects were thoroughly discussed, fostering a productive exchange of knowledge and insights.

On November 15, we were scheduled to fly to Basel in Switzerland but had to stay at a hotel in Frankfurt due to an issue with our flight. Ms. Lee from IBRA was extremely helpful with this. She also took us to the IBRA headquarters, where Executive Director, Mr. Vázquez, explained IBRA's history and brought us up to date with its current activity. We were not very familiar with IBRA previously, but we now understand the organization very well thanks to Mr. Vázquez.

In addition, Mr. Gonçalves gave us an impressive tour of Medartis and showed us the facility and implants.



In the evening, Ms. Lee took us on a short tour of Basel and kindly welcomed us to her home for a delicious dinner. It was during this meal that we had the pleasure of meeting Prof. Dr. med. Dr. Phil. Victor Valderrabano, the Chairman of this entire project.

The next day, Prof. Valderrabano drove us to Hospital Obach in Solothurn, Switzerland, and showed us his impressive 'maximally-invasive surgeries'. He shared his extensive knowledge in foot and ankle diseases and his unique treatment strategies with us. In the evening, we joined the faculty dinner and discussed many topics.

November 18 and 19 were dedicated to "Contemporary Challenges and Perspectives in Foot and Ankle Surgery". We had some fascinating, intellectual case discussions during the theoretical session of the course, and it was great to be joined by numerous virtual live-stream course participants.

In the practical session of the course, we tried VR technology to enhance hands-on training. First, the faculty members presented a variety of challenges in foot and ankle surgery, and we subsequently learned the appropriate options and techniques. Then, we moved to the wet lab in the University of Basel and started the indicated surgical procedures on a foot. Some of the procedures were completely new to us, and we performed them while discussing the process with group members and faculty members.

There was a networking dinner in the evening, with some incredible discussions with faculty members and participants. After dinner, we were awarded with the diploma of scientific collaboration between IBRA European Training Centers. This is one of the greatest honors we have ever received. The last day was the same wet lab course, and we had similar but different experiences in this practical course. The program ended with a special lunch with participants and faculty members, and we promised we would see each other again soon.

The entire project was well designed and organized, and we definitely had one of the greatest experiences in foot and ankle surgery. We were tremendously impressed not only by the high quality of knowledge and techniques shared with us but also the heartfelt hospitality. We would highly recommend taking part in this program and would be pleased to help if anyone has any questions or queries.

ABOUT THE AUTHORS



Dr. Hiromu Ito MD. PhD.
Head of the Department of
Orthopedic Surgery
Kurashiki Central Hospital
Clinical Professor of the
Department of Orthopedic Surgery
Kyoto University Hospital, Japan

Dr. Masato Ogawa MD. PhD.
Head of the Department of
Orthopedic Surgery
Laketown Hospital
Koshigaya, Japan

IBRA Report

Christian K. Spies, August 7–11, 2023, Wrightington Hospital NHS Foundation Trust, UK

My week-long IBRA-sponsored observership took place from August 7 to August 11 of this year. Professor Adam Watts specializes in upper limb surgery and is Research and Governance Lead of the Upper Limb Department at Wrightington Hospital, which is a tertiary referral center in Northern England regarding upper and lower limb surgery. The Wrightington Hospital has become famous for the first modern hip replacement operation which was performed by Sir John Charnley. The senior staff consists of highly trained and educated specialists for every joint of the upper and lower limbs. Professor Watts is responsible for the upper limb governance and therefore teaches fellows during their rotation.

After getting clearance from the administration office I was warmly welcomed by Professor Watts on the first day. He took me and a fellow from New Zealand to the operating theater. The first thing I have noticed was the open and relaxed atmosphere. Professor Watts is very passionate about teaching his fellows and is mindful of preparing them to work on their own. I joined them in the doctors' mess to discuss the list of patients for the day. The first patient had a comminuted olecranon fracture and we shared our opinions regarding the different options, from conservative treatment to plate osteosynthesis. We engaged in an extensive and open discussion concerning this issue. It was certainly interesting to hear different opinions and ideas for treating the lesion. The tension band suturing of the olecranon fracture, which was eventually performed, really caught my attention and I may apply this technique in my daily practice. We had another very profound and informative discussion based on the second case on the list which was a comminuted distal humerus fracture. I have learned very interesting aspects about the indications for hemiarthroplasty of the distal humerus which is the preferred option for frail, elderly patients. Total elbow replacements may be a better choice for active, elderly patients and open reduction/internal fixation should be the primary goal for younger and active patients. I found this treatment algorithm very appropriate and methodical for addressing these types of injuries. The last patient on the list had a septic loosening of an elbow prothesis which was removed and an antibiotic-laden cement spacer was implanted.

The following morning, I joined Dr. Mike Hayton in the operating room and I had the opportunity to observe a wide variety of hand surgery procedures. First, there was a Dupuytren-3-finger contracture, which was solved smoothly with partial fasciectomy and Z-plasties, followed by a wrist arthroscopy. Then an interposition arthroplasty of the wrist for osteoarthritis, fusion of the CMC-1-joint and an open carpal tunnel release were performed in the same session. The CMC-1-joint fusion technique was particularly intriguing regarding the bone preparation and reduction of the arthrodesis.

The day ended with an implantation of a silicone spacer for the PIP joint and a DIP joint fusion in the same finger. We shared different ideas regarding the approach to the PIP joint and the choice of implant.

On Wednesday, I joined Professor Watts in clinic. I had the chance to experience the procedural work-flow in a British outpatient clinic and had the opportunity to observe clinical management and Professor Watts' decision-making process. We discussed different diagnostic procedures for distal biceps tendinopathy, for peripheral nerve compression of the upper limb, and for rheumatoid arthritis of the elbow.

On my fourth day I had the opportunity to observe a challenging second revision operation due to loosening of a total elbow prothesis in combination with insufficiency of the triceps muscle. It was a pleasure to observe the issue solved very elegantly using an Achilles tendon allograft while Professor Watts taught his fellows during the surgery. The second operation was a distal comminuted humerus fracture, which was reconstructed facilitating the posterior approach with the olecranon osteotomy. Double plating of the fracture was applied and the tension band suturing for the olecranon osteotomy was used. On my last day, I was able to spend another day in the operating theatre with Professor Watts. Again, the patient's pathology was very interesting. The patient, a professional athlete, suffered from an extension deficit at the elbow joint based on a combination of anterior joint capsule contracture and posterior osteophytes at the olecranon and fossa, in addition to cubital tunnel syndrome. First, an open in-situ release of the nerve was performed, before the elbow joint was released arthroscopically.

Overall, this observership was incredibly informative and valuable. I would like to thank Professor Adam Watts and Dr. Mike Hayton for their time and effort in making my stay a truly wonderful experience for me.

Furthermore, I would like to thank Mrs. Diane Allmark for managing all organisational issues.

Finally, I would sincerely like to thank the International Bone Research Association (IBRA) for making this outstanding experience possible. It was a great educational trip with many interesting aspects. I had the opportunity to meet colleagues who excel in their profession, giving me the chance to broaden my professional network.

ABOUT THE AUTHOR

PD Dr. med. Christian K. Spies (FEBHS)
Spital Langenthal
Spital Region Oberaargau SRO AG
St. Urbanstrasse 67
4900 Langenthal, Switzerland

IBRA RESIDENT COURSE

Osteosynthesis of the Hand & Wrist

Recommended for senior residents and physicians in subspecialty training.
The course offers the basics in clinical diagnostics, treatment, and follow-up.
The focus is on state-of-the-art surgical techniques.

January 25–26, 2024
Zurich, Switzerland

More information can be found at: https://www.ibra.net/Events

IBRA Introduces New Application Process for Full Membership: Accessing Exclusive Benefits Made Easier

IBRA has long been recognized as a leading organization in the field of orthopedics and traumatology. With a mission to promote bone and tissue management, IBRA offers a range of membership options to cater to the diverse needs of healthcare professionals worldwide. Recently, IBRA's Board of Directors (BoD) made a significant update to the application process for its IBRA Full Membership, aiming to make it more accessible for surgeons who would like to join this prestigious network of surgeons.

Previously, aspiring Full Members were required to secure endorsements from two existing IBRA Full Members. This requirement posed a challenge for many surgeons who were eager to become part of IBRA's vibrant community. However, in a move towards inclusivity, and to expand its reach, IBRA has now removed this endorsement requirement.

There is a new, streamlined application process for Full Membership. Surgeons can now apply directly by registering on IBRA's official website at https://www.ibra.net/membership-registration. This change eliminates any barriers that may have hindered talented surgeons from becoming Full Members, ensuring that IBRA remains at the forefront of bone research and tissue management by welcoming diverse perspectives.

IBRA Full Membership offers an array of benefits to its members. In addition to the privileges provided to Basic Members, Full Members gain access to all IBRA courses at a significantly reduced rate of 50 percent. This exclusive discount provides a valuable opportunity for surgeons to enhance their professional development and keep up to date with the latest developments in their field. Moreover, IBRA Full Members serve as the "voting body" of the IBRA General Assembly, giving them a voice in shaping the future of the organization.

To further foster inclusivity, IBRA offers reduced membership fees for surgeons from low-income countries and lower-middle-income countries. The standard rate for Full Membership is CHF 150 per year, while eligible countries can enjoy a reduced fee of CHF 100 per year. Depending on the registration date, a corresponding price reduction per quarter is also possible.

For healthcare professionals who are already IBRA Basic Members and would like to upgrade to Full Membership, the process is even simpler.

Instead of filling out a membership registration form, you can directly send your CV in English to info@ibra.net. This streamlined approach facilitates the transition and allows Basic Members to enjoy all the enhanced benefits and opportunities available to Full Members.

IBRA's commitment to recognizing excellence and fostering professional growth is further demonstrated through its Premium Membership. Surgeons who have contributed significantly to IBRA's faculty or have become board members are eligible for Premium Membership. This exclusive tier encompasses all the benefits of Basic and Full Membership, and the best part is that it is free of charge, forever. It is a token of our appreciation for those who have made substantial contributions to IBRA's success.

In conclusion, IBRA's new Full Membership application process marks a significant step toward inclusivity and accessibility within the organization. By removing the endorsement requirement and introducing a simplified application process, IBRA opens its doors to a wider range of talented surgeons, ensuring a diverse and vibrant community dedicated to advancing bone research and tissue management. Surgeons around the world now have a direct pathway to accessing exclusive benefits, participating in IBRA courses, and contributing to the organization's decision-making processes. Join IBRA today and become part of a global network dedicated to shaping the future of orthopedics and traumatology.

IBRA – An International Transdisciplinary Network in Continuing Medical Education and Research

The **I**nternational **B**one **R**esearch **A**ssociation is an independent non-profit organization for specialized surgeons and research scientists.

Our core activities are a wide range of medical courses and multinational symposia, scholarship programs, and research projects focusing on:

- clinical management (traumatology and orthopedic surgery)
- materials research, including hardware development
- biomechanics and engineering

Our emphasis is primarily on Head, Upper Limbs, and Lower Limbs.

Continuing Medical Education

IBRA offers a variety of educational events around the globe, which are headed
by a multinational faculty. Examples include:

- level-oriented medical education courses
- practical surgical workshops
- national and international congresses and symposia
- webinars

IBRA 2024 Curriculum

This overview shows the number of planned courses in 2024 for surgeons from different regions (international) as well as for Latin America, Europe, Middle East and Asia Pacific in the segments Head/CMF, Upper Limbs, and Lower Limbs, sorted according to education level.

Master Course

Target Audience
Recommended for senior surgeons and department heads

Main Specialty
An interactive seminar and hands-on workshop, addressing trauma and reconstruction with representative cases and discussions. The international faculty presents the latest innovations, and provides an opportunity to exchange experiences with participating senior surgeons

Objective
Re-thinking good practices, promoting improvements

Advanced Course

Target Audience
Recommended for fellows, attendings/consultants

Main Specialty
Faculty members first classify the injury or deformity, and then share their preferred approach, treatment, and follow-up of cases with advanced levels of difficulty

Objective
Handling challenging cases

Resident Course

Target Audience
Recommended for senior residents and physicians in sub-specialty training

Main Specialty
The course offers the basics in clinical diagnostics, treatment, and follow-up. The focus is on state-of-the-art surgical techniques.

Objective
Learning state-of-the-art interventions

LATAM

x 1 Head
x 2 Upper Limbs
x 1 Lower Limbs

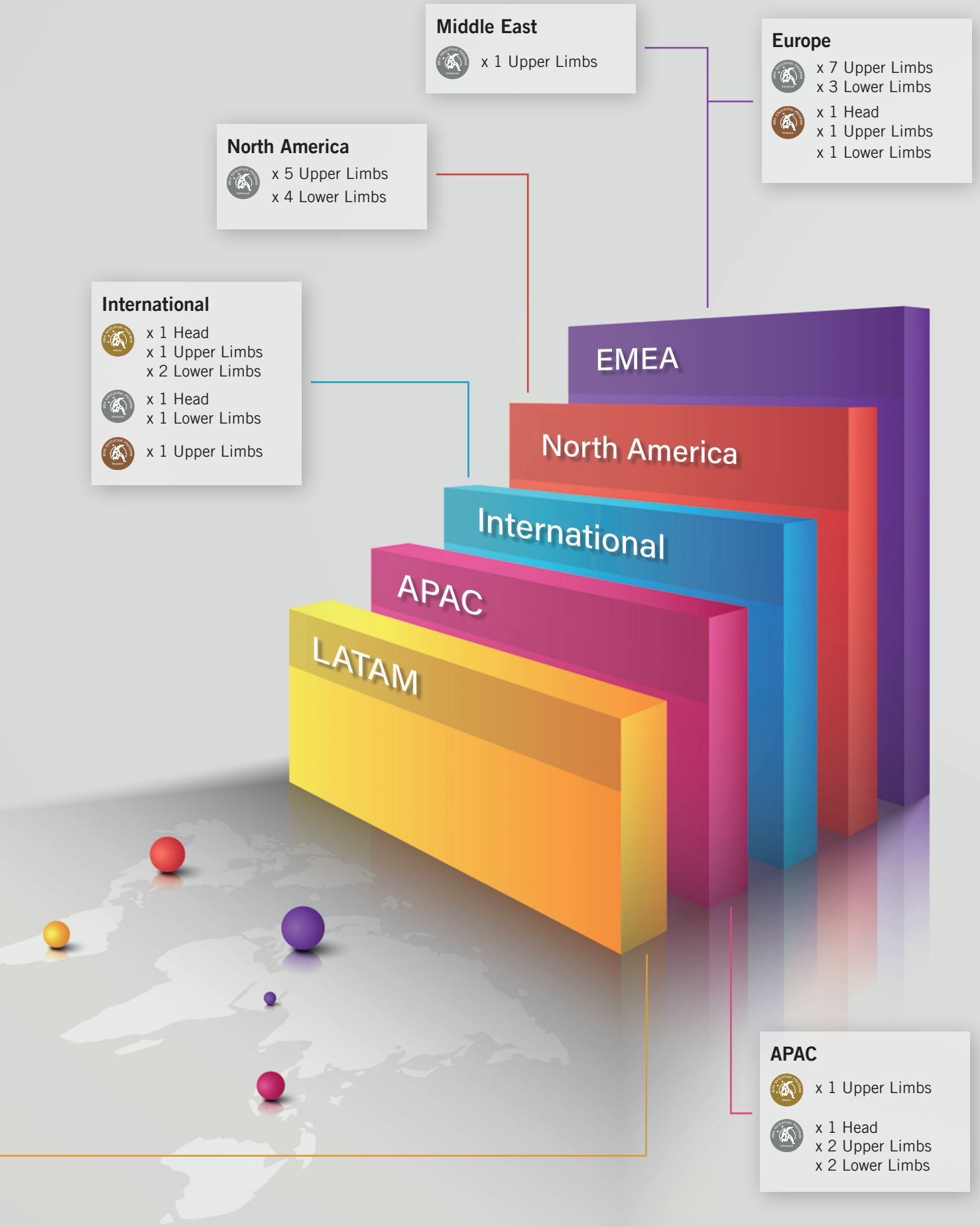
Middle East
x 1 Upper Limbs
Europe
x 7 Upper Limbs
x 3 Lower Limbs
x 1 Head
x 1 Upper Limbs
x 1 Lower Limbs
North America
x 5 Upper Limbs
x 4 Lower Limbs
International
x 1 Head
x 1 Upper Limbs
x 2 Lower Limbs
x 1 Head
x 1 Lower Limbs
x 1 Upper Limbs
EMEA
North America
International
APAC
LATAM
APAC
x 1 Upper Limbs
x 1 Head
x 2 Upper Limbs
x 2 Lower Limbs

Empowering Members through Information and Connection

Stay Informed, Stay Ahead: Embracing a Global Network of Knowledge

As the world of medical research and education continues to advance at an unprecedented pace, it has become more crucial than ever for our members to stay informed and connected. In our quest to foster a global community of collaboration and knowledge-sharing, IBRA offers a diverse range of communication channels, ensuring that our esteemed members can access regular updates and stay at the forefront of cutting-edge developments in the field.

1. Regular Newsletters: Empowering You with Knowledge

Our regular newsletters, thoughtfully curated and sent every month, stand as a testament to our commitment to empowering you with a wealth of invaluable insights. Our primary focus within these newsletters centers on bringing you the latest Continuing Medical Education (CME) opportunities. We understand that keeping up to date with the most recent educational offerings is essential for advancing your skills and expertise. Through these newsletters, you gain access to a comprehensive repository of CME courses, workshops, and conferences related to head and limb surgery. This not only saves you time but also ensures that you stay well-informed about educational opportunities that align with your professional interests and specialization.

Signing up to receive the IBRA newsletter is a straightforward process that offers two options: one for non-members and the other for IBRA Members.

1. Signing up for the Newsletter on the IBRA Website:

For individuals who are not yet IBRA Members, but would still like to stay informed and receive regular updates via the newsletter, please sign up on the IBRA website.

2. Becoming an IBRA Member:

Becoming an IBRA Member ensures a more comprehensive way to access the newsletter and a host of additional benefits. IBRA Membership includes subscription to the IBRA newsletter, as well as other exclusive opportunities within our community.

2. Social Media: Building Bridges across Borders

In today's interconnected world, harnessing the power of social media is imperative for fostering a sense of unity among our members around the globe. IBRA is actively present on two prominent platforms: LinkedIn and Instagram. These platforms act as dynamic forums for intellectual discussions, event highlights, and updates from our Training Centers around the world. By following IBRA on social media, you can engage in lively discussions, network with peers from different corners of the world, and gain access to exclusive updates and announcements. Let us join hands, transcending geographical boundaries and time zones, to build a united front in our pursuit of better patient care.

Follow us on:

3. News Page and Event Agenda: Navigating the Realm of Opportunities

IBRA's website stands as a beacon of information, equipped with a dedicated News page and a comprehensive Event Agenda. The latter ensures that you never miss out on exciting opportunities to expand your horizons. It lists upcoming conferences, seminars, webinars, and workshops, empowering you to participate in events that resonate with your interests and expertise.

IBRA Event Calendar

Head

Upper Limbs

Lower Limbs

4. IBRA Virtual Campus: Providing Lifelong Learning

Embracing the boundless possibilities of e-learning, the IBRA Virtual Campus offers a plethora of educational resources at your fingertips. As an IBRA Member, you gain unlimited access to this treasure trove of knowledge, unlocking a world of continuous learning opportunities.

The IBRA Virtual Campus houses an extensive array of e-learning materials, tailored to cater to the diverse needs of our global community. Here, you will find a growing collection of recorded webinars, webcasts, and online courses, as well as a rich library of scientific articles, case discussions, and instructional videos. Whether you want to deepen your understanding of the latest developments or acquire specialized skills, the IBRA Virtual Campus provides a flexible and accessible means to achieve your professional aspirations.

Navigating the IBRA Virtual Campus is effortless, as it can be accessed through the exclusive IBRA Member Area. As a testament to our commitment to your growth and development, access to the IBRA Virtual Campus is provided free of charge to all IBRA Members. Embrace this unique opportunity to cultivate your expertise, elevate your career, and foster a lifelong passion for learning.

Access to the IBRA Virtual Campus:

A Case of Charcot-Marie-Tooth Disease with Atypical Progressive Collapsing Foot Deformity (PCFD)

Simone Santini, Victor Valderrabano, Mario Herrera-Pérez

INTRODUCTION

Charcot-Marie-Tooth disease (CMT) is a heterogeneous group of inherited peripheral neuropathies characterized by progressive degeneration and dysfunction of peripheral nerves.[1] It affects both motor and sensory nerves, leading to muscle weakness, sensory loss, and other neurological abnormalities.[2] In the most common form of CMT, pes cavus is the most prevalent foot deformity.[3] However, in some individuals with CMT, progressive collapsing foot deformity (PCFD) can also occur due to muscle imbalances and weakness.[4] Progressive collapsing foot deformity (PCFD), historically known as adult-acquired flatfoot deformity (AAFD) is a condition characterized by various degrees of hindfoot valgus, midfoot abduction, and forefoot varus.[5] Several conservative and surgical treatments have been described.[6] In cases of severe deformity, gross instability, or arthritic joint, a medial column arthrodesis, which consists of a fusion of the talonavicular (TN), navicular-cuneiform (NC), and first tarsometatarsal (TMT 1) joint, can be indicated[7]. Here, we report a case of Charcot-Marie-Tooth disease with atypical progressive collapsing foot deformity (PCFD) and medial column osteoarthritis.

CASE PRESENTATION

A 57-year-old woman presented with pain in her left foot refractory to previous conservative treatments. No allergies or significant comorbidities. Clinically, PCFD with marked midfoot abductus, pain at the palpation of the medial arch joints and a drop foot. Single heel-rise test was negative, no significant Achilles tendon shortening. Weight-bearing radiographs showed medial column OA. (Fig. 1) In view of the difficulties during ambulation and the uncontrolled pain, the patient was scheduled for a medial column fusion and a tibialis posterior tendon (PTT) transfer.

MANAGEMENT AND OUTCOMES

The patient was positioned supine with a tight tourniquet inflated at 250 mmHg. The medial arch bones were identified and marked. (Fig. 2) A straight incision was performed from the first metatarsal diaphysis to the talar neck. Care must be taken during the deep dissection to avoid injuring the neurovascular bundle (the medial dorsal cutaneous nerve's medial branch is frequently encountered during medial column procedures) and the tibialis anterior insertion on the medial cuneiform.

The TN, NC and TMT 1 joint capsules were then opened, and, with the help of a K-wire spreader with 2.0 mm K-wires (Fig. 3), each joint was prepared for fusion. Care must be taken to thoroughly prepare the joint surfaces, removing cartilage and exposing the subchondral bone. Drilling the surfaces with a K-wire is also recommended to improve bleeding and fusion chances.

At this point, the joints were manually compressed proximo-distal and held in position with 2.0 mm K-wires. Any residual gap was filled with autologous bone mixed with allograft cancellous chips. (Fig. 4) A medial column fusion plate (Medartis, Switzerland) was used in this surgery. The plate was bent according to the patient's anatomy and temporarily fixed with 2.0 mm olive K-wires bicortically. (Fig. 5) Compression forceps were then used to apply compression over the joints from proximal to distal. (Fig. 6) The plate was pulled to the bone with two 3.5 mm cortical screws in the talus. The remaining screw holes for final fixation of the plate were filled with 3.5 mm Trilock screws. The X-ray results can be seen in Fig. 7 (A and B). The PTT transfer was then performed. (Fig. 8)

The TP was detached at its insertion, then a first cut was made 4 cm proximal to the medial malleolus to proximally deliver the tendon. A second cut was made on the lateral tibia surface and was more distal. The PTT was tunneled through the interosseous membrane out from this access. A third cut was eventually performed on the III cuneiform, in order to achieve tendon to bone fixation with a reabsorbable screw. It was paramount that the foot was held in dorsiflexion during this last procedure to fix the PTT in tension. The surgical exposure was closed using metallic clips, and a cast was made to hold the foot in 90° of dorsiflexion.

CASE DISCUSSION

Foot and ankle surgeons frequently perform medial column arthrodesis for a number of etiologies, such as PCFD and post-traumatic or degenerative arthritis.[8,9] Significant information has been published on medial column arthrodesis that describes various fixation methods, but there is a scarcity of literature on using plate fixation for medial column arthrodesis.[9]

In our experience, this procedure is the most stable and reliable in cases of compromised bone (osteopenic, neuropathic bone) although it requires an extended approach, with consequent concerns about poor wound healing and infection. Fusing three joints with one plate can be a complex procedure, it is therefore crucial to use a plate that can be bent according to the patient's anatomy.

TTP transfer is a reliable procedure for treating foot drop, achieving good results in terms of patient satisfaction and normal gait.[10] Several surgical techniques have been described with substantial overlap in terms of results: in this case, the tendon was routed across the interosseous membrane (another option is to use a circumtibial route) and fixed directly to the bone (another option is to perform a tendon-to-tendon anchorage).[10]

I would like to express my gratitude to Prof. Herrera for explaining the procedure step by step and sharing tips and tricks that only an expert surgeon can have. I would also like to thank the entire foot and ankle unit at University Hospital of the Canary Islands in Tenerife for their kindness and patience while broadening my horizons.

Lastly, I would like to thank Prof. Valderrabano for making this experience possible.

Fig. 1) Dorso-plantar (A) and lateral (B) view, left foot. Severe OA and medial arch collapse.

Fig. 2) Medial arch bones were identified and marked.

Fig. 3) K-wire spreader with 2.0 mm K-wires.
This system allows good visualization of the joints, making it easier to prepare the articular surfaces.

Fig. 4) Joints were manually compressed and temporarily fixed with 2.0 mm K-wires. Any residual gap was filled with autologous bone mixed with allograft cancellous chips.

Fig. 5) A medial column fusion plate (Medartis, Switzerland) was used in this surgery. The plate was bent according to the patient's anatomy and temporarily fixed with 2.0 mm olive K-wires bicortically.

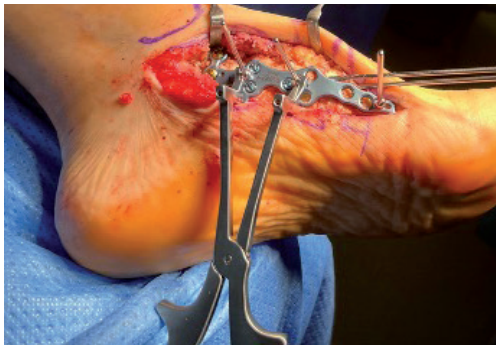

Fig. 6) Compression forceps were used to apply compression over the joints starting from the TN joint.

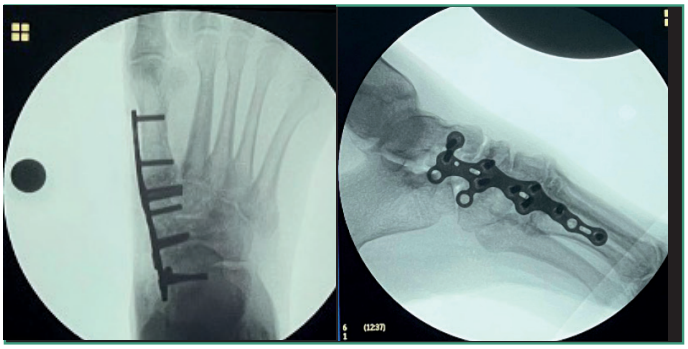

Fig. 7) Final dorso-plantar (A) and lateral (B) view after plate positioning.

Fig. 8) PTT transfer.

REFERENCES

1. *Holmes JR, Hansen ST.*
   Foot and ankle manifestations of Charcot-Marie-Tooth disease.
   Foot Ankle 1993 Oct;14(8):476–86.

2. *Casasnovas C, Cano LM, Albertí A, Céspedes M, Rigo G.*
   Charcot-Marie-tooth disease.
   Foot Ankle Spec. 2008 Dec;1(6):350–4.

3. *Maranho DA, Volpon JB.*
   Acquired Pes Cavus In Charcot-Marie-Tooth Disease.
   Rev Bras Ortop. 2009 Jan;44(6):479–86.

4. *Eschler A, Wussow A, Ulmar B, Mittlmeier T, Gradl G.*
   Intramedullary medial column support with the Midfoot Fusion Bolt (MFB) is not sufficient for osseous healing of arthrodesis in neuroosteoarthropathic feet.
   Injury. 2014 Jan;45 Suppl 1:S38–43.

5. *Myerson MS, Thordarson DB, Johnson JE, Hintermann B, Sangeorzan BJ, Deland JT, et al.*
   Classification and Nomenclature: Progressive Collapsing Foot Deformity.
   Foot Ankle Int. 2020 Oct;41(10):1271–6.

6. *Espinosa N.*
   Treatment of a Progressive Collapsing Foot Deformity.
   Ther Umsch. 2022 Sep;79(7):315–23.

7. *Lendrum JA, Hunt KJ.*
   Medial Column Fusions in Flatfoot Deformities: Naviculocuneiform and Talonavicular.
   Foot Ankle Clin. 2022 Dec;27(4):769–86.

8. *de Moraes Barros Fucs PM, Svartman C, de Assumpção RMC, Yamada HH, Simis SD.*
   Surgical Technique: Medial Column Arthrodesis in Rigid Spastic Planovalgus Feet.
   Clinical Orthopaedics and Related Research®. 2012 May;470(5):1334.

9. *Nasser EM, LaPorta GA, Trott K.*
   Medial Column Arthrodesis Using an Anatomic Distal Fibular Locking Plate.
   The Journal of Foot and Ankle Surgery. 2015 Jul;54(4):671–6.

10. *Agarwal P, Gupta M, Kukrele R, Sharma D.*
    Tibialis posterior (TP) tendon transfer for foot drop: A single center experience.
    J Clin Orthop Trauma. 2020;11(3):457–61.

ABOUT THE AUTHORS



Dr. Simone Santini
Department of Orthopedic and Trauma Surgery
University Campus Bio-Medico of Rome
Rome, Italy

Prof. Dr. Dr. Victor Valderrabano
Swiss Ortho Center, Swiss Medical Network
Schmerzklinik Basel
Basel, Switzerland

Prof. Dr. Mario Herrera-Pérez
Head Foot and Ankle Unit
Orthopedic Department
University of La Laguna
San Cristóbal de La Laguna
Tenerife, Spain

Guyon's Canal Syndrome – An Unusual Cause

Alejo Garcia Bensi, Pablo López-Osornio, Joaquin Casañas

SUMMARY

This case report is an unusual cause of Guyon's canal syndrome. The patient attended the consultation for weakness and grip loss in his left hand, causing him to drop objects on a daily basis. His strength was altered without trauma. We carried out specific studies of his hand. During the MRI, a double arterial kinking was observed and determined to be an unusual cause of compression of the ulnar motor branch in Guyon's canal. This was then confirmed by EMG, and surgery was indicated to recover his strength. The kinking was visualized during surgery and determined as the cause of his illness. The ulnar motor branch was released while being very careful of ischemia. In the immediate postoperative period, a dorsal splint was used to protect the site, and after three weeks we checked the results of his grip, which had increased by 50%. Approximately four months later, he recovered full grip strength.

Keywords: Guyon's canal, Cubital syndrome, Kinking, Ulnar syndrome, Ulnar surgery

INTRODUCTION

Guyon's canal syndrome is a complex of symptoms leading to the progressive impairment of the ulnar nerve function, secondary to chronic, mechanical lesion of the nerve within Guyon's canal.[1] Guyon's canal syndrome is a relatively rare condition, and a musculoskeletal disorder of the upper limbs.[2,3] Ulnar nerve compression neuropathy is caused by direct compression in Guyon's canal also known as handlebar palsy (seen in cyclists).[4,5] Especially in downhill cycling, a large proportion of body weight is supported by the hand on the handlebars, leading to an increased pressure at Guyon's canal resulting in compression of the ulnar nerve.[6] The incidence or prevalence rates for Guyon's canal syndrome are not reported in literature. The most common compression causes include ganglion cyst (80% of non-trauma causes), lipoma, repetitive trauma, ulnar artery thrombosis or aneurysm, hook of hamate fracture or nonunion, pisiform dislocation, inflammatory arthritis, fibrous band, muscle or bony anomaly, congenital bands, palmaris brevis hypertrophy, and idiopathic conditions.

Anatomy and Zones:

Guyon's canal is approximately 4 cm long, and begins at the proximal extent of the transverse carpal ligament and ends at the aponeurotic arch of the hypothenar muscles. The ulnar nerve bifurcates into the superficial sensory and deep motor branches.[7,8,9] The deep branch of the ulnar nerve innervates all of the interosseous muscles and the third and fourth

Boundaries of Guyon's canal	
Floor	Transverse carpal ligament, hypothenar muscles
Roof	Volar carpal ligament
Ulnar border	Pisiform and pisohamate ligament, abductor digiti minimi muscle
Radial border	Hook of hamate

Zones of Guyon's canal			
Zone	*Location*	*Causes of Compression*	*Symptoms*
Zone 1	Proximal to bifurcation of the nerve	Ganglia and hook of hamate fractures	Mixed motor and sensory
Zone 2	Surrounds deep motor branch	Ganglia and hook of hamate fractures	Motor only
Zone 3	Surrounds superficial sensory branch	Ulnar artery thrombosis or aneurysm	Sensory only

(Strohl, A. B., & Zelouf, D. S. (2017). Ulnar Tunnel Syndrome, Radial Tunnel Syndrome, Anterior Interosseous Nerve Syndrome, and Pronator Syndrome. Journal of the American Academy of Orthopaedic Surgeons, 25(1), e1–e10).

lumbricals. It also innervates the hypothenar muscles, the adductor pollicis, and the medial head (deep) of the flexor pollicis brevis (FPB). Presentation varies based on the location of compression within Guyon's canal and may be purely motor, purely sensory, or both.[7,8,9,10,11,12] Symptoms: Pain and paresthesia in ulnar 1-1/2 digits, weakness to intrinsics, digital flexion to the ring and little finger and thumb adduction, clawing of ring and little fingers caused from loss of intrinsics flexing the MCP and extending the IP joints. The Allen test must be used to help diagnose ulnar artery thrombosis as well as a neurovascular assessment. Ulnar nerve palsy resulting in paralysis of the intrinsic muscles (adductor pollicis, deep head FPB, interossei, and fourth and fifth lumbricals), weakened grasp from loss of MP joint flexion power, weak pinch from loss of thumb adduction (as much as 70% of pinch strength was lost).[13] Tinel's sign: based on the existence of pain by wrist percussion over the course of ulnar nerve.[14,15] Froment's sign: IP flexion compensating for loss of thumb adduction when attempting to hold a piece of paper, loss of MCP flexion and adduction by adductor pollicis (ulnar n.) compensatory IP hyperflexion by FPL (AIN). Jeane's sign: a compensatory thumb MCP hyperextension and thumb adduction by EPL (radial n.) compensates for loss of IP extension and thumb adduction by adductor pollicis (ulna n.). Wartenberg sign: abduction posturing of the little finger.[16] Imaging is very important for diagnosing the cause of the compression, including radiographs, CT, MRI, Doppler ultrasound.[17] NCS and EMG are also very helpful investigations in establishing diagnosis and prognosis, threshold for diagnosis, conduction velocity <50 m/sec across elbow and low amplitudes of sensory nerve action potentials and compound muscle action potentials.[18]

CASE PRESENTATION

A 53-year-old male with no personal history presented with weakness in the wrist and fourth and fifth fingers as well as poor agility and function of his left hand. It started three months ago, no trauma, falls or any other evident cause. The patient also had flexion of fourth and fifth proximal interphalangeal joints, and a mild preacher's hand was observed. He was unable to hold objects for a short period of time. Clinical findings were first finger abductor (abductor pollicis longus) and interossei muscles with abductor digiti minimi (ADM) intact, Duchenne's sign and Froment's sign were positive. EMG confirmed an exclusive motor ulnar nerve branch distal denervation, and ADM without any findings or alterations. MRI determined triple arterial kinking with double ulnar modification and simple kinking in the radial artery. Fig. 1. Surgery was indicated with nerve stimulator (intraoperative recording of ENG).

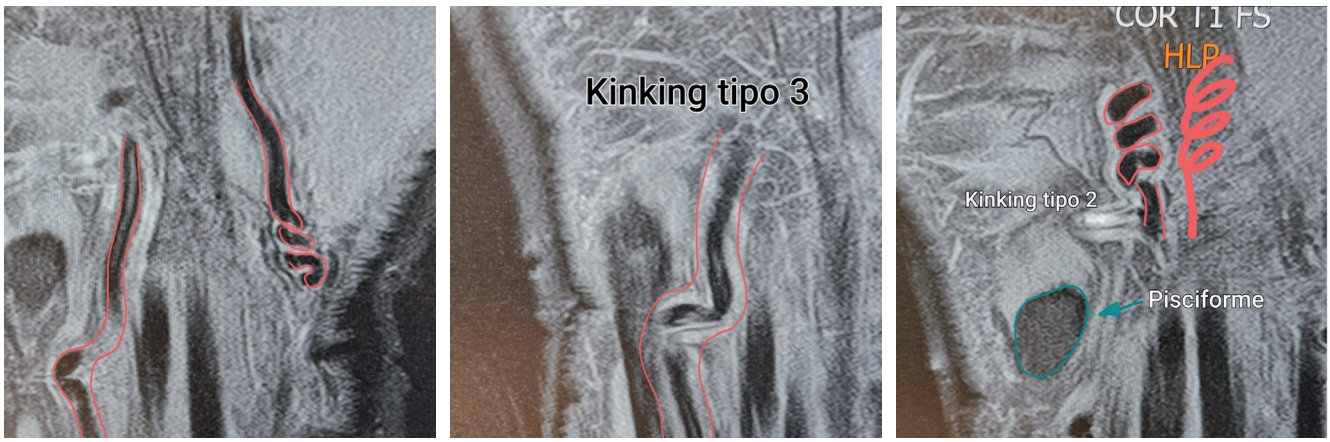

Fig. 1. A) MRI coronal plane of the left hand with kinking of the radial artery (right) and ulnar artery (left).
B) Kinking type III, ulnar artery.
C) Kinking type II, ulnar artery, pisiform bone (highlighted in blue).

MANAGEMENT AND OUTCOMES

Under regional anesthesia (axillary block), a pneumatic tourniquet was placed at the upper arm close to the armpit. The patient was placed supine with his left arm on a hand table. The ulnar approach was used.[19] The skin incision bordered the radial side of the flexor carpi ulnaris (FCU) tendon, diagonally crossed the proximal wrist crease, then followed longitudinally in the palm, in line with the ring finger. The fascia on the radial side of the FCU was opened, and the ulnar nerve and artery were identified just below the radial edge of the FCU. The nerve was traced from proximal to distal. The roof of Guyon's canal, the volar carpal ligament, was divided in line with the skin incision. The nerve and artery were carefully mobilized and explored. (Fig. 2). Intraoperative ENG, a low voltage potential was observed in the ulnar motor branch for the intrinsic muscles, with the exception of the ADM, which was intact. It is important to note that the compression was distal to the exit of the ulnar motor branch, nearly Zone 1. Neurolysis was carried out with the use of a microscope and the communication of the distal ulnar artery was ligated. This communicating artery was compressing the motor ulnar branch. The difference between ischemia or not is an important reason to believe that when the pneumatic tourniquet was released, the arterial morphology was the cause of the compression, instead of only checking the nerve with ischemia. Using a ENG stimulator helped to understand the injury and most importantly where neurolysis should be performed. Finally, we performed subcutaneous and skin sutures, and finished with a dorsal splint. The patient was monitored for three weeks, with one follow-up appointment each week. In the second follow-up appointment, all stitches were removed and he underwent hand therapy three days after surgery. In the third week, the patient reported a good outcome from the surgery and that he could hold objects for a long period of time without any complications.

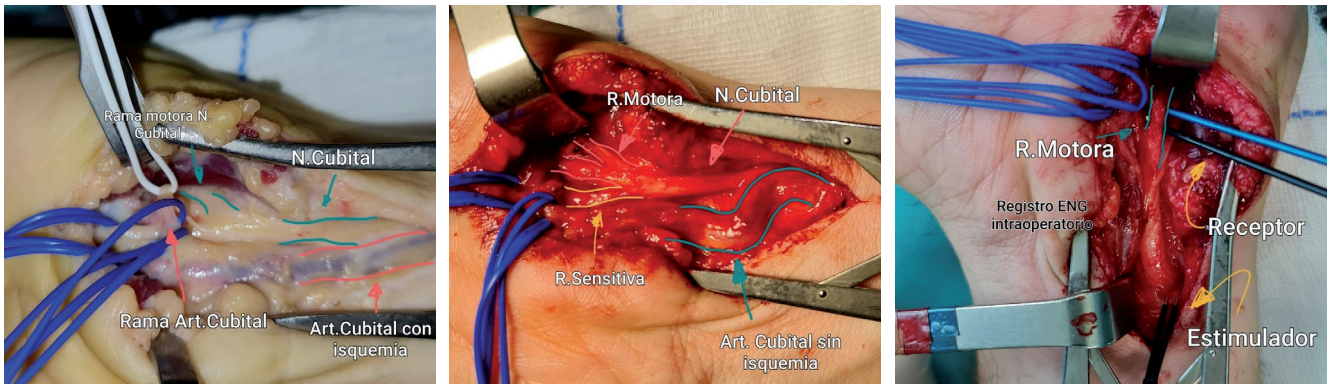

Fig. 2. A) Pneumatic tourniquet, ischemia, ulnar arterial branch (left red arrow), ulnar artery (right red arrow), ulnar motor branch (left blue arrow), ulnar nerve (right blue arrow).
B) No ischemia.
C) Nerve stimulator during surgery to check nerve potentials. Stimulator (yellow arrow pointing down) Receiver (yellow arrow pointing up).

DISCUSSION AND CONCLUSION

This case is important because it was an unusual cause of compression that was only selective to the ulnar motor branch instead of a mixed ulnar nerve injury. The main challenge was understanding why the patient suffered from weakness without any known traumas or taking part in sports, such as cycling. The only factor we strongly believe is that there was an external cause of compression, and a cyst in the affected area. Performing an MRI, and then reviewing these images, made it possible to identify that there was kinking in Guyon's canal. A differential diagnosis was made once the MRI images were obtained and we clearly defined the main compression with arterial kinking, and realized the presentation of unique ulnar motor branch compression. Using a microscope was an excellent resource for managing the nerve injury with extreme precision, and intraoperative EMG was used in combination for an excellent outcome. This excellent outcome started in the consulting room, making a differential diagnosis using EMG, MRI, etc. Medical semiology and specific tests performed on the patient were also important, and helped us to understand what to look for in specific studies. Sometimes we focus on certain common causes, and when we have something different, we start to understand that the patient is unique. This applies during surgery, to understand that some anatomical variants really exist, sometimes without complications, sometimes making some nerve or arterial compression.

ABOUT THE AUTHORS

Dr. Alejo Garcia Bensi
CLIMBA
Viamonte 1632
Buenos Aires, Argentina

Dr. Pablo López-Osornio
Teknon, Trauma Unit
Carrer de Vilana 12
Barcelona, Spain

Dr. Joaquin Casañas
Teknon, Trauma Unit
Carrer de Vilana 12
Barcelona, Spain

IBRA MASTER COURSE

Realistic Treatment of Wrist and Elbow Fractures

Recommended for senior surgeons and department heads.
An interactive seminar and hands-on workshop, addressing trauma and reconstruction with representative cases and discussions. The latest innovations and trends are presented both in theoretical discussions and surgical demonstrations. Practical exercises are designed as close as possible to real-life scenarios in the operating room (preoperative discussion of the case, use of pre-fractured or deformed specimen).

November 8–9, 2024
Basel, Switzerland

More information can be found at: https://www.ibra.net/Events

REFERENCES

1. *Depukat P., Mizia E., Kłosiński M., Dzikowska M., Klimek-Piotrowska W., Mazur M., Kuniewicz M., Bonczar T.*
   Anatomy of Guyon's canal — a systematic review.
   Folia Med Cracov. 2014; 2: 81–86.

2. *Bozkurt MC, Tagil SM, Ozcakar L, et al.*
   Anatomical variations as potential risk factors for ulnar tunnel syndrome: a cadaveric study.
   ClinAnat 2005;18:274–80.

3. *Huisstede BM, Miedema HS, Verhagen AP, et al.*
   Multidisciplinary consensus on the terminology and classification of complaints of the arm, neck and/or shoulder.
   Occup Environ Med 2007;64:313–19.

4. *Kalainov DM, Hartigan BJ.*
   Bicycling-induced ulnar tunnel syndrome.
   Am J Orthop 2003;32:210–11.

5. *Akuthota V, Plastaras C, Lindberg K, et al.*
   The effect of long-distance bicycling on ulnar and median nerves: an electrophysiologic evaluation of cyclist palsy.
   Am J Sports Med 2005;33:1224–30.

6. *Capitani D, Beer S.*
   Handlebar palsy—a compression syndrome of the deep terminal (motor) branch of the ulnar nerve in biking.
   J Neurol 2002;249:1441–5.

7. *Gross MS, Gelberman RH*
   The anatomy of the distal ulnar tunnel. Clin
   Orthop Relat Res 1985;196:238–247.

8. *Murata K, Shih JT, Tsai TM.*
   Causes of ulnar tunnel syndrome: A retrospective study of 31 subjects.
   J Hand Surg Am 2003; 28(4):647–651.

9. *Balogh B, Valencak J, Vesely M, Flammer M, Gruber H, Piza-Katzer H.*
   The nerve of Henle: An anatomic and immunohisto-chemical study.
   J Hand Surg Am 1999;24(5):1103–1108.

10. *Strohl AB, Zelouf DS (2017).*
    Ulnar Tunnel Syndrome, Radial Tunnel Syndrome, Anterior Interosseous Nerve Syndrome, and Pronator Syndrome.
    Journal of the American Academy of Orthopaedic Surgeons, 25(1), e1–e10

11. *Aleksenko D, Varacallo M.*
    2023 May 22. Guyon Canal Syndrome.
    Treasure Island (FL): StatPearls Publishing; 2023 Jan.

12. *Atkins SE, Logan B, McGrouther DA.*
    The deep (motor) branch of the ulnar nerve: a detailed examination of its course and the clinical significance of its damage.
    J Hand Surg Eur Vol 2009 Feb.

13. *Cobb T.*
    Guyon's Canal Revised: an anatomic study of the carpal ulnar neurovascular space.
    J Hand Surg Am. 1996 Sep.

14. *Davis EN, Chung KC.*
    The Tinel sign: a historical perspective.
    Plast Reconstr Surg. 2004; 114 (2): 494–499.

15. *Alfonso M, Dzwierzynski W.*
    Hoffman-Tinel sign. The realities.
    Phys Med Rehabil Clin N Am. 1998; 9 (4): 721–736.

16. *Voche P, Merle M.*
    Wartenberg's Sign. A new method of surgical correction.
    J Hand Surg. 1995; 20B, 1: 49–52

17. *Shen L, Masih S, Patel DB, Matcuk GR*
    MR anatomy and pathology of the ulnar nerve involving the cubital tunnel and Guyon's canal.
    Clin Imaging 2016 Mar–Apr.

18. *Tapadia M, Mozaffar T, Gupta R.*
    Compressive Neuropathies of the Upper Extremity: Update on Pathophysiology, Classification, and Electro-diagnostic Findings.
    J Hand Surg 2010; 35A: 668–677.

19. *Mackinnon SE.*
    Nerve Surgery. Chap 10 page 251.

Revision Nonunion ORIF for Scaphoid Waist Fracture Utilizing a Volar Carpal Artery Vascularized Graft

Michelle Zeidan

INTRODUCTION

Scaphoid fractures represent the most common carpal bone fracture, typically occurring after a fall onto an outstretched hand. A large proportion of these fractures occur at the waist of the scaphoid. While the majority of these go on to uneventful union, there is still about a 5–15%[1] nonunion rate, due to the tenuous, retrograde blood supply of the scaphoid. Nonunions of the scaphoid can pose a difficult problem. Most surgeons would agree that for nonunions with humpback deformity or cystic changes, bone grafting is likely necessary. There are a large variety of bone grafting options, including non-vascularized and vascularized options. Options include distal radius bone graft, iliac crest bone graft, 1,2-intercompartmental supraretinacular artery pedicled graft, medial femoral condyle pedicled graft, the volar carpal artery graft, as well as others.[2,3]

Keywords: Scaphoid nonunion, Vascularized bone graft, Volar carpal artery, SNAC wrist

CASE PRESENTATION

I chose the following case for a variety of reasons. First, there is a significant amount of literature about this topic, and so there is a lot to read about, from diagnosis to management to postoperative care. Second, this case led to numerous interesting discussions with the consultant during the case about their management of nonunions and choice of graft. Lastly, my experience to this point has mainly been with cancellous or corticocancellous grafting or MFC grafts. I have not had much exposure to local pedicled grafts and so this was an interesting case for me to see and read more about.

The first reported use of a vascularized bone graft (VBG) in the wrist was by Roy-Camille in 1965, using the scaphoid tubercle on an abductor pollicis brevis muscle pedicle.[3,4] There are several advantages to vascularized bone grafts, including transfer of preserved osteocytes, increased perfusion, accelerated graft consolidation, and improved delivery of osteogenic and angiogenic properties.[3] The distal radius is incredible in that is has a complex leash of vascularity, allowing both dorsal and volar vascularized graft options. Indications for the use of VBGs in the treatment of scaphoid nonunion include a failed previous conventional graft or AVN of the proximal pole.[5]

This is a case of an 18-year-old male who presented to the clinic with chronic pain in his wrist. He had previously had a scaphoid fracture, that went on to nonunion. This was then treated with ORIF with cancellous grafting approximately a year previously. He presented with persistent pain as well as limited range of motion, with about 30 degrees of extension and 60 degrees of flexion.

Imaging showed a nonunion of the waist of the scaphoid with prior screw fixation. He had both DISI deformity, with humpback and cystic changes within the scaphoid with no significant arthrosis of the radioscaphoid joint. Due to the chronic nature of the nonunion, as well as persistent symptoms, the patient was indicated for nonunion revision ORIF. As he had already undergone prior nonunion ORIF that had failed, the decision was to proceed with a local vascularized bone graft.

The patient was taken to the operating room and placed supine on a hand table. The prior volar incision was used and the screw was removed. The scaphoid nonunion was thoroughly debrided and showed good bleeding bone on both proximal and distal fragments. The defect was measured and the appropriately sized volar carpal artery vascularized bone graft was elevated (see details below). This was then inset into the scaphoid defect and a screw was placed retrograde across the fracture site. A radiolunate pin was placed for maintenance of neutral lunate alignment from his prior DISI.

The patient was placed in a volar splint, discharged the day of surgery, and his immediate postoperative course was unremarkable. His follow-up appointment at two weeks showed his incision was healing well and he remained immobilized. Long-term follow-up will hopefully show a healed scaphoid nonunion. The plan is to obtain a CT to evaluate healing at around 12 weeks.

Volar distal radius bone grafts are a viable solution for scaphoid nonunions. The ultimate goal of nonunion ORIF is to heal the fracture and restore carpal geometry, intrascaphoid angle, and scapholunate angle.[6] There are four possible options, with the volar carpal artery graft being one of the more common ones.[7] It is a vascularized graft off the radial branch of the volar carpal artery, harvested from the volar ulnar distal radius epiphysis, 0.5–1.5 cm proximal to the joint and just distal to the pronator quadratus. The mean length of the pedicle is about 3 cm, allowing sufficient mobilization for placement within a scaphoid nonunion.[7]

A study of nine patients who underwent volar carpal artery VBG and volar plating revealed bone union in 8/9 patients, patient satisfaction in 8/9 patients, improved grip strength compared to the preoperative period, and similar flexion and extension compared to the preoperative period.[8] Another study of nine patients showed union in all patients, improvement in pain in all patients, and significant improvement in Mayo wrist scores in all patients.[9] Another study of 15 proximal pole scaphoid nonunions with AVN showed 84% of scaphoids went on to union at 12 weeks, and all had correction of humpback deformity and improvement in carpal geometry measures, including intrascaphoid angles and SL angles.[10] A study in France on 111 cases shows results similar to the above studies.[11]

Overall, this was an interesting case for me to see and to learn more about local vascularized bone graft options for scaphoid nonunions. I think this is definitely something I will add to my graft options. I think that a local vascularized

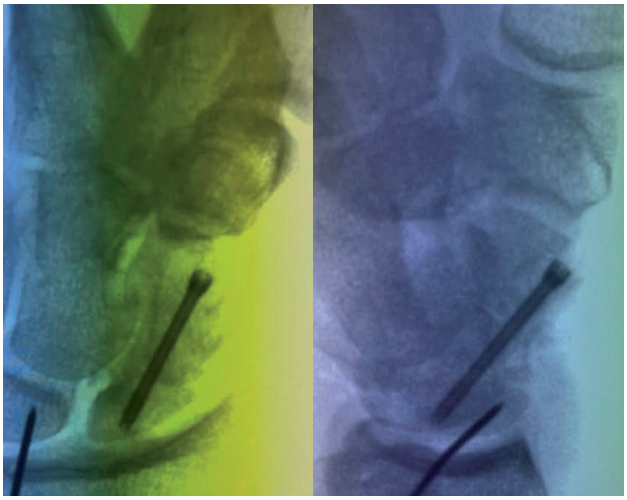

option will likely be my next choice for a revision nonunion where a nonvascularized graft has failed or there is a proximal pole with AVN. As I would choose to go volar for most nonunions to help correct the humpback deformity, I would feel a lot more comfortable doing a volar carpal artery graft after reviewing this case. I think the only other possible change I would make is using a locking plate instead of a screw in the setting of revision or primary nonunion surgery.

This is just one of several interesting cases I saw during my month in Australia. I am very grateful for this opportunity and cannot thank IBRA enough for making it possible.

ABOUT THE AUTHOR

Dr. Michelle Zeidan
CORE Institute University of Arizona
200 W Monroe St Apt 1703
Phoenix AZ, 85003

REFERENCES

1. *Steinmann SP, Adams JE.*
   Scaphoid fractures and nonunions: diagnosis and treatment.
   J Orthop Sci. 2006;11(4):424–431.

2. *Sgromolo NM, Rhee PC.*
   The Role of Vascularized Bone Grafting in Scaphoid Nonunion.
   Hand Clin. 2019;35(3):315–322.

3. *Derby BM, Murray PM, Shin AY, et al.*
   Vascularized bone grafts for the treatment of carpal bone pathology.
   Hand N Y N. 2013;8(1):27–40.

4. *Alluri RK, Yin C, Iorio ML, Leland H, Mack WJ, Patel K.*
   A Critical Appraisal of Vascularized Bone Grafting for Scaphoid Nonunion.
   J Wrist Surg. 2017;6(3):251–257.

5. *Payatakes A, Sotereanos DG.*
   Pedicled vascularized bone grafts for scaphoid and lunate reconstruction.
   J Am Acad Orthop Surg. 2009;17(12):744–755.

6. *Karaismailoglu B, Fatih Guven M, Erenler M, Botanlioglu H.*
   The use of pedicled vascularized bone grafts in the treatment of scaphoid nonunion: clinical results, graft options and indications.
   EFORT Open Rev. 2020;5(1):1–8.

7. *Elzinga K, Chung KC.*
   Volar Radius Vascularized Bone Flaps for the Treatment of Scaphoid Nonunion.
   Hand Clin. 2019;35(3):353–363.

8. *Dodds SD, Halim A.*
   Scaphoid Plate Fixation and Volar Carpal Artery Vascularized Bone Graft for Recalcitrant Scaphoid Nonunions.
   J Hand Surg. 2016;41(7):e191–e198.

9. *Dailiana ZH, Malizos KN, Zachos V, Varitimidis SE, Hantes M, Karantanas A.*
   Vascularized Bone Grafts From the Palmar Radius for the Treatment of Waist Nonunions of the Scaphoid.
   J Hand Surg. 2006;31(3):397–404.

10. *Sommerkamp TG, Hastings H, Greenberg JA.*
    Palmar Radiocarpal Artery Vascularized Bone Graft for the Unstable Humpbacked Scaphoid Nonunion With an Avascular Proximal Pole.
    J Hand Surg. 2020;45(4):298–309.

11. *Gras M, Mathoulin C.*
    Vascularized bone graft pedicled on the volar carpal artery from the volar distal radius as primary procedure for scaphoid non-union.
    Orthop Traumatol Surg Res. 2011;97(8):800–806.

IBRA ADVANCED COURSE

Unsolved Challenges of the Wrist: Making Sense and Management of Enigmatic Problems

Recommended for hand fellows and attending surgeons. This course offers ideal conditions for the introduction and consolidation of surgical techniques. Participants will learn about current treatment concepts and new internal fixation techniques. Experienced surgeons will provide three theoretical sessions and scientific discussions on Day One. This advanced course also includes cutting-edge presentations on managing fractures, dislocations, and instability, and it reconstructs challenging problems in the hand and wrist. Day Two will give attendees the opportunity to apply their newly-acquired skills and expertise to fresh specimens under directed instruction. In the second part of Day Two, participants will divide into groups of four and take part in unique, hands-on anatomy sessions with real-life, pre-fractured specimens, with the aim of being able to manage these complex conditions.



January 26–27, 2024
Tampa Bay, FL, USA

Good Clinical Outcome after Operative Therapy of an Anterior Facet Fracture of the Coronoid Process: A Case Report

Sebastian Wegmann, Tim Leschinger, Lars Peter Müller, Michael Hackl

ABSTRACT

The anteromedial facet (AMF) of the coronoid process plays a vital role in the stabilization of the ulnohumeral articulation. Fractures often lead to chronic instability, especially if missed. In this study, we report on a case of operative treatment for an O'Driscoll subtype 2 fracture of a 25-year-old patient who sustained the injury during a fall onto his outstretched hand. The AMF fragment was addressed via a Hotchkiss approach. After anatomic reduction, the fragment was fixed with a cannulated screw and a coronoid plate. The anterior bundle of the ulnar collateral ligament (UCL) was intact. The posterior bundle of the UCL and the lateral collateral ligament (LCL) were torn from their humeral origins and were reattached with suture anchors. This case report illustrates the typical varus posteromedial rotatory mechanism leading to anteromedial facet fractures with concomitant disruption of the LCL complex and the posterior bundle of the UCL. Addressing all aspects of this osteoligamentous injury can lead to good and reliable clinical outcomes.

Keywords: Anteromedial facet, Coronoid, Coronoid fracture, Elbow, Instability, Lateral collateral ligament, Outcome

INTRODUCTION

In addition to the lateral collateral ligament (LCL) complex and the ulnar collateral ligament (UCL), the ulnohumeral articulation plays a vital role in stabilizing the elbow joint. A major part of the ulnohumeral articulation is represented by the coronoid process. Biomechanical and clinical studies have provided thorough insight in its crucial role as an anterior buttress of the elbow joint in preventing elbow dislocations.[1,2] An initial classification for coronoid fractures was presented by Regan and Morrey in 1989 depending on the fragment size measured in lateral radiographs.[3] O'Driscoll et al. later introduced a new classification evaluating coronoid fractures according to their anatomic location and the underlying injury patterns and identified three types: 1) tip fractures, 2) anteromedial facet (AMF) fractures, and 3) basal fractures. (Fig. 1)

AMF fractures are usually the result of a varus posteromedial injury mechanism and are therefore typically accompanied by ruptures of the LCL complex and the posterior bundle of the UCL. Displaced AMF fractures lead to pronounced instability.[4] According to the O´Driscoll classification three different subtypes can be described for AMF fractures: Rim fractures are subtype 1, rim and tip fractures are subtype 2 and fractures of the rim and the sublime tubercle are subtype 3.[5] Besides an increased awareness and interest in the injury, optimal treatment for AMF fractures is not well established, yet operative therapy indicated satisfactory functional outcomes.[6]

Coronoid Fracture Classification (O'Driscoll et al. 2003. AAOS ICL.)

Fracture Type	Fracture Subtype	Description
Tip	1	≤ approximately 2 mm of coronoid bony height (ie, flake fracture)
	2	> approximately 2 mm of coronoid height
Anteromedial	1	Anteromedial facet
	2	Anteromedial facet + tip
	3	Anteromedial facet + sublime tubercle (± tip)
Basal	1	Coronoid body and base
	2	Transulnar basal coronoid fractures

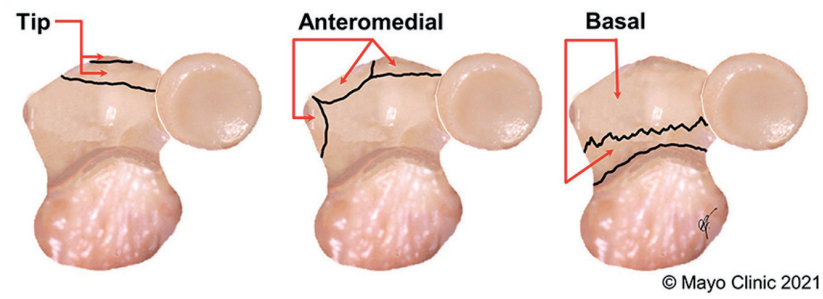

Fig. 1: O'Driscoll classification of coronoid fractures.

CASE PRESENTATION

In this study, we report on a case of a 25-year-old male patient who sustained an AMF fracture due to a fall onto his outstretched right hand. After initial treatment in another hospital with closed reduction and cast immobilization, the patient was referred to our institution (University Hospital Cologne, Germany). The CT scan showed an anteromedial facet fracture of the coronoid process, O'Driscoll subtype 2 (Fig. 2,3)

At the first clinical evaluation, the patient presented with a swollen elbow joint, reduced range of motion (ROM), and a slight radial nerve palsy (4+/5). Using both the clinical and radiological results, we determined acute posteromedial varus instability and therefore decided to perform surgery.

We chose a Hotchkiss approach for the coronoid process.[7] After skin incision over the medial epicondyle, and after incision of the fascia, both the medial antebrachial cutaneous nerve and the ulnar nerve were exposed and protected whilst kept intact in their sulcus to avoid postoperative iatrogenic instability. Access to the coronoid fragment was gained over Hotchkiss interval with preservation of the anterior bundle of the UCL. After irrigation of the fracture site, the main coronoid fragment was anatomically reduced and provisionally fixed by a K-wire (1.6 mm) in PA direction, and later, stabilized with a 40 mm cannulated screw. Subsequently, an Aptus 2.0 coronoid plate (Medartis) was fitted and fixed to the shaft with three screws. The main fragment was fixed with two locking screws. The small anterolateral fragment was an avulsion of the annular ligament and repaired with sutures through the lateral plate hole. While the anterior bundle of the UCL was intact, the posterior bundle was torn from its humeral origin and repaired with an all-suture anchor to fully restore posteromedial rotatory stability. Finally, the LCL was repaired through a separate, lateral incision with another all-suture anchor. Intraoperative clinical examination showed complete restoration of elbow stability over full range of motion and the intraoperative radiographs showed a congruent joint line with no tendency for redislocation of the elbow joint during dynamic testing. Subcutaneous fat and skin were closed in a routine manner. A cast was placed for one week. The postoperative radiographs showed a congruent joint.

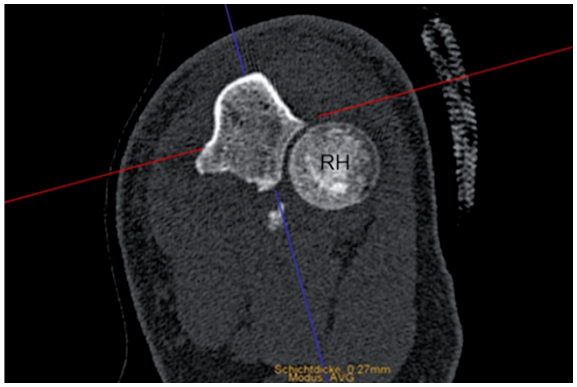

Fig. 2a) Axial CT scan with the radial head (RH) and the fracture line of the anteromedial rim and tip of the coronoid process.

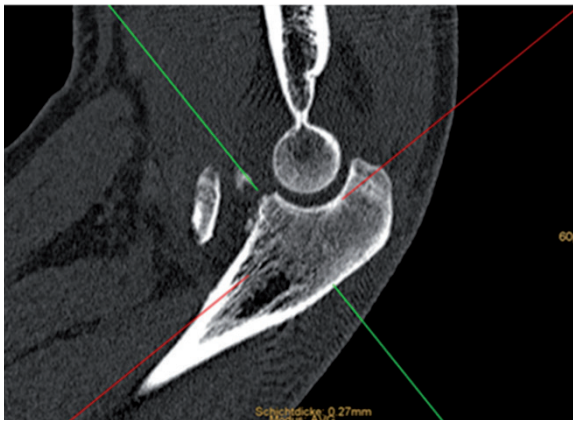

Fig. 2b) Sagittal CT scan showing the fracture of the coronoid process with the main fragment and an additional small anterolateral fragment.

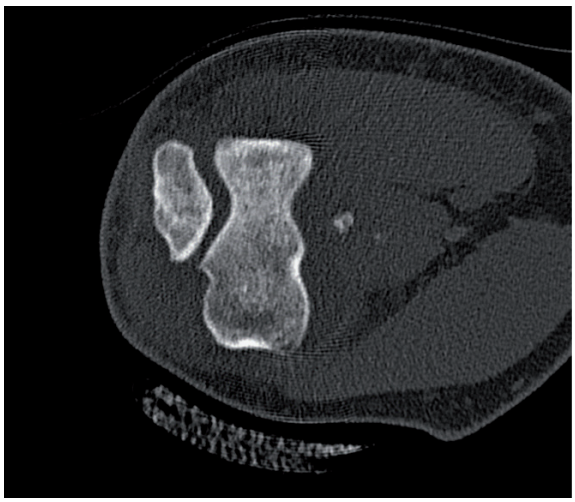

Fig. 3) On axial view, the typical posteromedial gapping of the ulnohumeral joint can be observed.

The patient was discharged three days later, while wound healing was uneventful, and instructed to change to a functional brace after one week to protect range of motion early with avoidance of varus and valgus forces. Loading was prohibited for six weeks, maximal load for 12 weeks. For the first week in the brace, an extension deficit of 40° with 120° of flexion was permitted. Extension was increased every week by 20°, reaching full ROM three weeks after surgery. Additionally, the patient was advised to follow the Overhead-Motion protocol autonomously.[8] Routine follow-up after six weeks showed a congruent joint on plain radiographs, clinically the patient had an extension deficit of 30° and the flexion was limited to 90° with a stable joint on varus and valgus stress. At a follow-up seven months after the initial operation, the joint was still congruent on X-ray, the patient had an improved range of motion (0-5–125° on extension/flexion and free pronation/supination) and no limitations in his everyday life. He had returned to all daily activities, including work and leisure activities.

MANAGEMENT AND OUTCOMES

Fractures of the coronoid process, especially anteromedial facet fractures pose a significant challenge for the elbow and trauma surgeon. Often the true extent of the injury is underestimated and the fracture neglected, leading to poor outcome and chronic instability. The main goal of treatment should be anatomical reduction within the ulnohumeral articulation and restoration of elbow stability. Delayed operative therapy should be avoided. Preoperative CT scans are mandatory in AMF fractures as initial radiographs cannot assess their extent. Lanzerath et al. suggested that AMF fractures are unstable lesions and due to their bony instability and additional ligament injuries should be addressed if the fracture is displaced.[9] An analysis of 24 patients undergoing surgery for AMF injuries by Klug et al. may confirm the good clinical results of open reduction and internal fixation of these fractures.[10] Our case may show that operative therapy can restore elbow stability with a good clinical outcome, yet proper evaluation of the fracture should always be performed using sectional imaging.

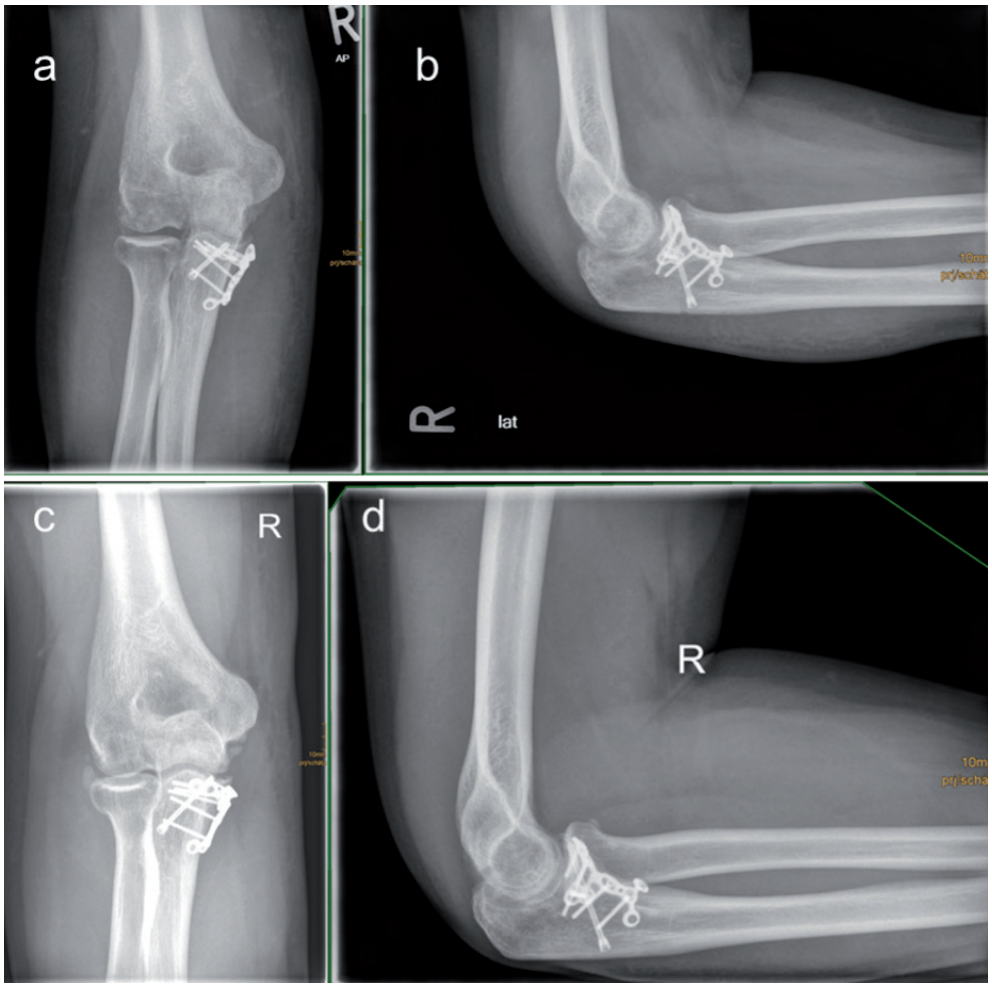

REFERENCES

1. *Pollock JW, Brownhill J, Ferreira L, McDonald CP, Johnson J, King G.*
   The effect of anteromedial facet fractures of the coronoid and lateral collateral ligament injury on elbow stability and kinematics.
   J Bone Joint Surg Am. 2009 Jun;91(6):1448–58.
2. *Closkey RF, Goode JR, Kirschenbaum D, Cody RP.*
   The role of the coronoid process in elbow stability. A biomechanical analysis of axial loading.
   J Bone Joint Surg Am. 2000 Dec;82(12):1749–53.
3. *Regan W, Morrey B.*
   Fractures of the coronoid process of the ulna.
   J Bone Joint Surg Am. 1989 Oct;71(9):1348–54.
4. *Kingery MT, Lowe DT, Egol KA.*
   Operative Fixation of the Anteromedial Facet of the Coronoid Process.
   J Orthop Trauma. 2022 Aug;36(Suppl 3):S7–8.
5. *O'Driscoll SW, Jupiter JB, Cohen MS, Ring D, McKee MD.*
   Difficult elbow fractures: pearls and pitfalls.
   Instr Course Lect. 2003;52:113–34.
6. *Lanzerath F, Hackl M, Wegmann K, Müller LP, Leschinger T.*
   The treatment of anteromedial coronoid facet fractures: a systematic review.
   J Shoulder Elbow Surg [Internet]. 2021;30(4):942–8. Available from: https://www.sciencedirect.com/science/article/pii/S1058274620307709
7. *Rausch V, Hackl M, Seybold D, Wegmann K, Müller LP.*
   Plattenosteosynthese des Processus coronoideus ulnae.
   Oper Orthop Traumatol [Internet]. 2020;32(1):35–46. Available from: https://doi.org/10.1007/s00064-019-00647-6
8. *Schreiber JJ, Paul S, Hotchkiss RN, Daluiski A.*
   Conservative management of elbow dislocations with an overhead motion protocol.
   J Hand Surg Am. 2015 Mar;40(3):515–9.
9. *Lanzerath F, Hochberger F, Ott N, Hackl M, Wegmann K, Müller LP, et al.*
   Anteromedial coronoid facet fractures and associated ligament lesions: A case series.
   Injury. 2023 Apr;
10. *Klug A, Buschbeck S, Gramlich Y, Buckup J, Hoffmann R, Schmidt-Horlohé K.*
    Good outcome using anatomically pre-formed buttress plates for anteromedial facet fractures of the coronoid-a retrospective study of twenty-four patients.
    Int Orthop. 2019 Dec;43(12):2817–24

ABOUT THE AUTHORS

Dr. Sebastian Wegmann



PD Dr. Tim Leschinger

Prof. Dr. Lars Peter Müller

PD Dr. Michael Hackl

University of Cologne, Faculty of Medicine and University Hospital Cologne
Department of Orthopedic and Trauma Surgery
Kerpener Straße 62, 50937, Cologne, Germany

Frontal Sinus Fractures: Clinical Considerations and Surgical Approaches to Reconstruction

Raphael Capelli Guerra, Henrique Cabrini Moreira, Henry Guevara García, Eduardo Hochuli Vieira, Andreas Neff, Philipp Jürgens, Bianca de Fátima Borim Pulino

ABSTRACT

Frontal sinus fractures are the result of high-energy injuries and are often associated with intracranial pathologies. Complex fronto-naso-orbital fractures comprise approximately 5% of all facial fractures, and the frontal sinus is frequently involved in these fractures. Due to its proximity to intracranial structures, inadequate treatment can lead to early or late intracranial infectious sequelae. The most common early sequelae are meningitis, encephalitis, and brain abscess. Other sequelae are persistent cerebrospinal fluid leakage, osteomyelitis, and meningoencephalocele. In addition, esthetic deformities can occur. This article aims to present the clinical case of a patient after a fall from standing height with comminuted fracture of the frontal sinus and roof of the orbit, reconstruction and postoperative follow-up without complications.

INTRODUCTION

Frontal sinus fractures are the result of high-energy injuries and are often associated with intracranial pathology, facial skeletal fractures, and visceral or limb injuries. Computed tomography (CT) is the standard of care for diagnosing these fractures and is essential to provide proper planning.[1] Complex fronto-naso-orbital fractures comprise approximately 5% of all facial fractures, and the frontal sinus is frequently involved in these fractures.[2] Because of its proximity to intracranial structures, inadequate treatment can lead to early or late intracranial infectious sequelae. The most common early sequelae are meningitis, encephalitis, and brain abscess. Other sequelae are persistent cerebrospinal fluid leakage, osteomyelitis, and meningoencephalocele. In addition, esthetic deformities can occur.[3] One-third of frontal sinus fractures involve the anterior wall only, and two-thirds affect the anterior or posterior wall and/or the frontonasal duct. Signs of such fractures include depression of the supraorbital area, anesthesia/paresthesia of the supraorbitals, orbital ecchymosis, and cerebrospinal fluid rhinorrhea. Minimally displaced fractures of the anterior wall of the frontal sinus that are not displaced are commonly managed with conservative treatment. More extensively displaced anterior wall fractures are treated using various techniques, which are progressing toward adequate reduction with fewer complications.[4]

CASE REPORT

A 75-year-old FLS patient suffered a fall from standing height with facial trauma, and received care at Leforte Morumbi Hospital. Initial treatment was performed by neurosurgery with a diagnosis of cranioencephalic trauma, without alterations in the computed tomography of the skull, and the patient was kept under observation for 12 hours. A computed tomography scan of the face revealed a longitudinal fracture trace in the left frontal bone (anterior wall of the frontal sinus), with bone subsidence of approximately 0.7 cm, noting the extension of the fracture to the supra medial wall of the orbit (Fig. 1a, 1b). The patient underwent surgery under general anesthesia one day after his facial trauma for reconstruction of a fracture of the frontal bone and roof of the left orbit.

The reduction and fixation of fractures were approached by the injury present in the frontal region at the time of the accident. The surgical approach made it possible to access the comminuted fracture traces of the frontal region and fracture in supraorbital margin (Fig. 2a), Medartis fixation materials were used for the reconstruction of the fractures (Fig.2b), the frontal sinus bone fragments were repositioned, and 1.5 mm fixation material was used, and a 1.5 mm orbital mesh was used to reconstruct the upper margin of the orbit (Fig. 3a, 3b). Postoperative computed tomography examination showed complete reconstruction of the fracture of the anterior wall of the frontal sinus and orbital reconstruction (Fig. 4). Patient progressed without visual alterations or complications.

CASE DISCUSSION

Usually the incidence of frontal sinus fractures has no distinction by sex, age, and cause of injury as with any patient with facial trauma. It is observed that in epidemiological studies, there are high levels of substance abuse, mainly alcohol and sometimes illegal drugs. In addition, high-speed driving and poor seat belt compliance are not uncommon.[5] The association with complex fractures of the face is frequent, mainly in traffic collisions, but also as a result of aggression.[6] Fractures involving the frontal sinus can cause complications related to the sinus and intracranial, orbital, and nasal structures. Their incidence ranges from 2% to 15% of all facial fractures. These are also the cranial fractures most often associated with facial fractures.[6,7] The goals of treatment are well established: isolation of intracranial contents, correction of cerebral spinal fluid leakage, prevention of infection and sequelae, restoration of functional integrity of the structures involved whenever possible, and restoration of frontal contour and esthetics.[2,8]

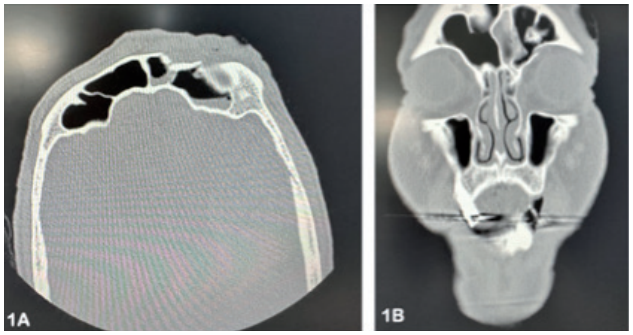

Fig. 1a, 1b) The computed tomography scan of the face revealed a longitudinal fracture trace in the left frontal bone (anterior wall of the frontal sinus), with bone subsidence of approximately 0.7 cm, noting the extension of the fracture to the supra medial wall of the orbit.

In general, anterior wall fractures are reconstructed, while posterior wall fractures and drainage system lesions are treated by sinus obliteration or cranialization.[9] However, immediate primary frontal bone and sinus reconstruction is becoming more widely accepted.[10]

The best treatment of frontal sinus fractures is controversial. This is due to the fact that sequelae may take several years to occur and involve intracranial structures with severe consequences. However, it should be noted that most frontal sinusitis and mucoceles that occur in the general population are not associated with trauma.[11] Furthermore, it is not easy to determine if a frontal sinusitis or mucocele will occur after a follow-up several years later or if it is indeed due to a traumatic event. In general, whatever technique is used, it is difficult, if not impossible, to follow a large series of patients over 20 years to verify the absence of complications.[6] Early initial treatment is believed to be important, and when the posterior wall is substantially intact, it is best to establish nasofrontal duct patency with a drainage tube.[12] Previous sinusitis and early age may contribute to failure, however the main reason for complications in this younger population exceeds the indication for sinus reconstruction. A postoperative CT scan is advisable even when the patient is asymptomatic.[1] Early complications are uncommon and the need for long-term follow-up is warranted. Frontal sinus reconstruction with or without cannulation of the nasofrontal ducts, as needed, is a good technique, provided that the posterior wall is not excessively comminuted, displaced, or grossly unstable and that the area of the injured nasofrontal duct is not beyond repair. Most significant complications occur due to incorrect indications for reconstruction.

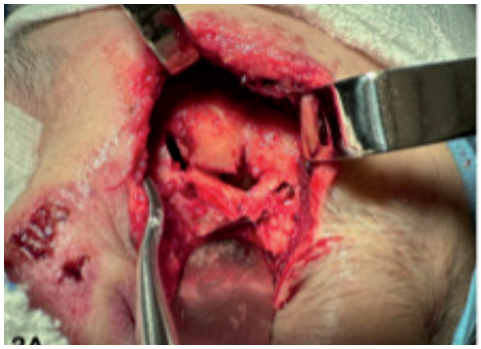

Fig. 2a) The reduction and fixation of fractures were approached by the injury present in the frontal region at the time of the accident. The surgical approach made it possible to access the comminuted fracture traces of the frontal region and fracture in supraorbital margin.

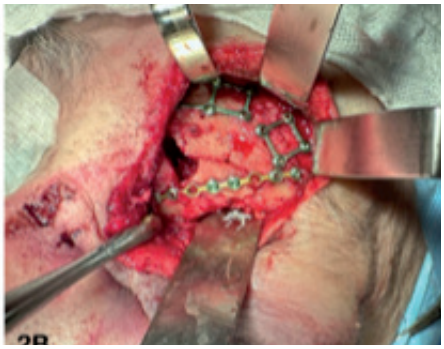

Fig. 2b) Medartis fixation materials were used for the reconstruction of the fractures.

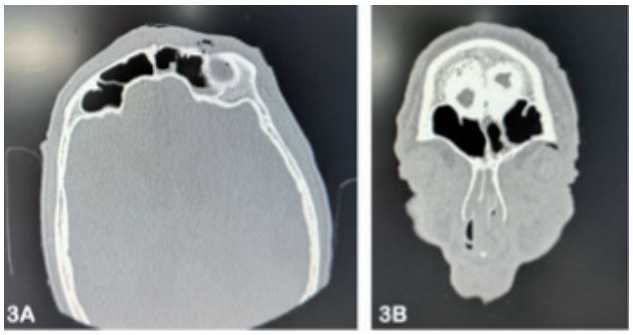

Fig. 3a, 3b) The frontal sinus bone fragments were repositioned and 1.5 mm fixation material was used, and 1.5 mm orbital mesh was used to reconstruct the upper margin of the orbit.

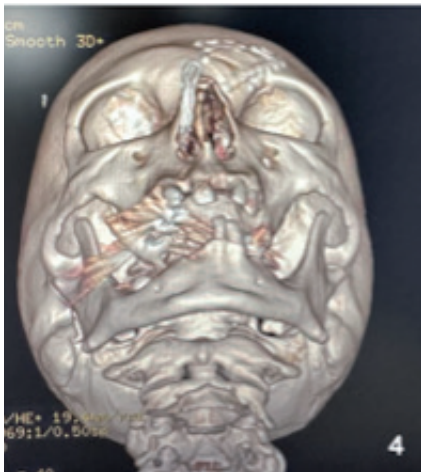

Fig. 4) Postoperative computed tomography examination showed complete reconstruction of the fracture of the anterior wall of the frontal sinus and orbital reconstruction.

ABOUT THE AUTHORS

Prof. Dr. Raphael Capelli Guerra
Institute of Teaching and Research
Sírio Libanês Hospital
Leforte Group
São Paulo Metodista University
São Paulo, Brazil

Dr. Henrique Cabrini Moreira
Arthur Ribeiro Saboya Hospital,
São Paulo, Brazil
Central Sul Rede D'Or Hospital,
São Paulo, Brazil
Federal University of São Paulo, Brazil



Dr. Henry Guevara García
Children's Orthopedic Hospital
La Floresta Medical Institute
Caracas, Venezuela

Prof. Dr. Eduardo Hochuli Vieira
São Paulo State University
Leforte Group
Araraquara, Brazil

Prof. Dr. Dr. Andreas Neff
Department of Oral and Maxillofacial Surgery
University Hospital Marburg UKGM GmbH
Marburg, Germany

Prof. Dr. Dr. Philipp Jürgens
MKG am Arabellapark
Munich, Germany

Dr. Bianca de Fátima Borim Pulino
São Paulo State University; Leforte Group
São Paulo Metodista University
São Paulo, Brazil

REFERENCES

1. *Johnson NR, Roberts MJ.*
   Frontal sinus fracture management: a systematic review and meta-analysis.
   International Journal of Oral & Maxillofacial Surgery [Internet]. 2021;50(1):75–82. Available from: https://doi.org/10.1016/j.ijom.2020.06.004
2. *Ioannides C, Freihofer HP, Friens J.*
   Fractures of the frontal sinus: a rationale of treatment.
   1993;
3. *Spinelli G, Lazzeri D, Arcuri F, Agostini T.*
   Closed reduction of the isolated anterior frontal sinus fracture via percutaneous screw placement.
   2015;79–82.
4. *Therapy C.*
   Frontal Sinus Injuries: Associated Injuries and Surgical Management of 93 Patients.
   2004;882–91.
5. *Pisano J TP.*
   Management of Panfacial, Naso-Orbital-Ethmoid and Frontal Sinus Fractures.
   Atlas Oral Maxillofac Surg Clin North Am. 2019;27(2):83–92.
6. *Francisco M, Gabrielli R.*
   Immediate Reconstruction of Frontal Sinus Fractures: Review of 26 Cases.
   2004;582–6.
7. *Kambalimath DH, Sridhar KR AS.*
   Surgical Management of Frontal Bone Fractures.
   J Craniofac Surg. 2021;32(4):1472–5.
8. *Podolsky DJ MK.*
   Frontal Sinus Fractures.
   Semin Plast Surg. 2021;7(35):274–83.
9. *Ioannides C FH.*
   Fractures of the frontal sinus: classification and its implications for surgical treatment.
   Am J Otolaryngol. 1999;20(5):273–80.
10. *Vincent A, Wang W, Shokri T, Gordon E, Inman JC DY.*
    Management of Frontal Sinus Fractures.
    Facial Plast Surg. 2019;35(6):645–50.
11. *Dedhia RD, Morisada MV, Tollefson TT SE.*
    Contemporary management of frontal sinus fractures.
    Curr Opin Otolaryngol Head Neck Surg. 2019;27(4):253–60.
12. *Gerbino G, Roccia F, Benech A CC.*
    Analysis of 158 frontal sinus fractures: current surgical management and complications.
    J Craniomaxillofac Surg. 2000;28(3):133–9.

IBRA ADVANCED COURSE

Orthognathic Surgery

Recommended for attending physicians/consultants. The course offers current concepts in clinical diagnostics, treatment and follow-up. The focus is on state-of-the-art surgical techniques. The course starts with clinical anatomy. Based on expressed needs by participants of previous courses and events (evaluations), residents and physicians in training request and appreciate „hands-on“ workshops, explanations of experts, the exchange with a variety of faculty as well as discussions with peers about clinical cases.



April 18–19, 2024
Mexico City, Mexico

More information can be found at: https://www.ibra.net/Events

Orthognathic Surgery in Patients with Reduced Dentition or Edentulous Jaws

Johannes Kleinheinz, Susanne Jung, Claudius Middelberg, Thomas Stamm

INTRODUCTION

Changing lifestyles, changing expectations of quality of life, and changes in health conditions mean that older patients are opting for jaw surgery as well as the classic age group of 18–25 years. However, the growing number of older patients is also associated with an increasing change of clinical situations, such as reduced dentition and even edentulous jaws. Indications are slightly different to the indications of the younger age group. In older patients, it is quite common to perform surgery in order to improve the prosthodontic care and its future prospects. In some cases, orthognathic surgery is the only way to establish implant-based restorations when great discrepancies in the transverse and sagittal plane are present. We see the need for pre-prosthetic treatment to create a solid base for prosthesis. In some cases, previously inserted implants need to be repositioned in the surrounding jaw bone to improve jaw relation. We also see cases with rare diseases or malformations with reduced dentition and no physiological base to the bone. Changes in individual preventative health care can also lead older patients to opt for a consultation. Finally, changes in life planning are associated with an increasing acceptance of surgery to meet the ideal of beauty and attractiveness, even in older age.

CLASSIFICATION

Clinical manifestations can be divided into the following categories:

1. Missing front teeth (Fig. 1)

These cases usually present an esthetic problem. In the case of preserved supporting zones, special attention must be paid to the canines, which are incredibly important for further prosthodontic treatment.

Fig. 1) Missing front teeth and class III relationship.

2. Missing premolars/molars (Fig. 2)

In this group, free-end situations and gaps can lead to the loss of supporting zones and thus posterior vertical dimension.

3. Unilateral tooth loss (Fig. 3)

Fig. 2) Missing premolars and molars, loss of supporting zone, and class III relationship.

Unilateral tooth loss can lead to tilting of the occlusal plane and thus to asymmetrical changes in the occlusal plane, resulting in esthetic problems.

Fig. 3) Unilateral teeth loss and transversal asymmetry.

4. Edentulous jaws (Fig. 4)

Uni or bimaxillary edentulism can result in mostly vertically noticeable alveolar ridge atrophy, and can also lead to pseudoprogenia in the sagittal plane.

Fig. 4) Edentulous jaws with pseudoprogenia.

5. Multiple tooth agenesis (Fig. 5)

Multiple missing teeth are often related to syndromes or rare diseases, such as ectodermal dysplasia.

Fig. 5) Case with ectodermal dysplasia, multiple missing teeth, and a class III relationship.

In all these groups, we can find additional accompanying findings, such as bone atrophy, implants in an unfavorable skeletal relation (Fig. 6), or periodontal problems. (Fig. 7)

Treating this special group of patients presents new challenges for the entire team.

Fig. 6) Edentulous jaws restored with implants in a pronounced class III bite relationship.

Fig. 7) Severe periodontal damage.

PLANNING PHASE

It is important to consider other factors in addition to the chief complaints. The main objective may be an optimized three-dimensional correction of jaw relation, especially the vertical dimension, for a planned prosthetic treatment. For this reason, in most cases it makes sense to perform backward planning and use the intended final prosthetic restoration as an aid for planning jaw relocations. (Fig. 8) The intended prosthetic concept (fixed restoration, removable restoration, implant-supported restoration) must also be included in the planning. For the timing of an implant placement, the early insertion and osseointegration of implants, before osteotomy, is considered to provide additional support for the subsequent postoperative retention phase.[1] Even a healing period of three to six months can be considered acceptable in view of orthodontic pretreatment in conventional cases. The planning of movements and the final position of the jaws should be performed by all three team members i.e. orthodontist, prosthodontist, and surgeon. Special attention should be paid to the retention phase with reduced dental support. The extended use of splints, the use of implant-supported prostheses, and tooth-supported restorations are all possible options.

PRETREATMENT

Since the majority of patients are of an advanced age, the possibility of existing periodontal disease is very high. Therefore, a sufficient periodontal pretreatment must be undertaken in any case, during which the restoration and stabilization of remaining teeth should also be carried out, and their loadability for orthodontic or prosthodontic treatment should be determined. The option for orthodontic pretreatment is usually limited because of a reduced number of teeth or existing fixed restorations. The limitation of dental anchorage may be reduced by early implant insertion. Prosthodontic appliances can stabilize the condylar position and restore the lost occlusal plane in advance. The concept of timing depends on the planned restoration (fixed or removable) and specifies whether the restoration is to be made before or after surgery.

SURGERY

The available osteotomies are the same as in conventional treatment cases, but must sometimes be adapted to the individual situation. Bone atrophy requires shorter osteotomy lines to avoid unfavorable splitting or fragmenting of the jaws, minimized periosteal stripping protects the blood supply of the bone.[2] When placing the fixation plates, interference with the prosthodontic restoration must be considered. The fixation follows the same basic principles, with a tendency to use more stable plates to consider unphysiologic postoperative loading via prosthesis and the missing dental securing. Patient-specific plates in combination with waferless surgery can also be used, but it must be taken into account that their application may require a wide exposure of the bone surface.[3] A longer period of immobilization using IMF screws may be beneficial, because crowns and bridges prevent tooth-borne fixation possibilities via orthodontic brackets.[4,5] The postoperative stabilization of the planned jaw relation and the position of the alveolar ridges are the key factors in this type of orthognathic surgery. Splints or prosthesis should fill the edentulous areas with denture saddles.[6,7,8] (Fig. 9) The need for hardware removal depends on the type and location of the used plates. It is necessary in cases of interference with prosthodontic rehabilitation, and often not necessary in cases with implant-supported restorations.

POSTOPERATIVE TREATMENT

In order to avoid relapses, a secure retention of the achieved positions of the jaws is required over a longer period. Problems arise in cases with removable dentures due to muscular dislodging forces and sometimes unreliable stability because patients stop wearing the devices. In addition, tissue-worn appliances tend to support gingival dents due to the changing soft tissue after surgery, i.e., swelling and shrinking. Another problem is restricted cleaning accessibility during the first weeks after surgery when the jaws are immobilized. This leads to impaired oral health and impacts on patients' quality of life.

CONCLUSIONS

The number of patients with reduced dentition or edentulism who would like orthognathic surgery will increase as motivations, individual life plans, and life demands change, and older patients increasingly present for consultation. The challenges of treating this age group are the lack of dental support in some cases, the limited possibility of orthodontic pretreatment, prosthodontic-driven treatment planning, and the critical retention phase. Nevertheless, stable and satisfactory long-term results can be achieved if the specifically modified prerequisites are taken into account.

REFERENCES

1. *Ahmad AG, Osman M, Awadalkreem F.*
   Orthognathic correction and corticobasal implant-supported prostheses as a treatment modality for partial edentulism with mandibular prognathism: a case report and review of literature.
   Int J Surg Case Rep. 2022;95:107219.
2. *Zhu Z, Ni S, Sun X, Wu G.*
   Posterior mandibular segmental split osteotomy: a novel technique for edentulous space reconstruction in patients with skeletal Class III malocclusion.
   J Craniofac Surg. 2022;33(7):e712–e714.
3. *Ho JPTF, Schreurs R, Baan F, de Lange J, Becking AG.*
   Splintless orthognathic surgery in edentulous patients – a pilot study.
   Int J Oral Maxillofac Surg. 2020;49(5):587–594.
4. *Jung MH, Baik UB, Ahn SJ.*
   Treatment of anterior open bite and multiple missing teeth with lingual fixed appliances, double jaw surgery, and dental implants.
   Am J Orthod Dentofacial Orthop. 2013;143(4 Suppl): S125–S136.
5. *Erkan M, Karaçay Ş, Atilla OA, Uzel G, Ülkür E, Yıldırım E.*
   Orthognathic surgery of a patient with oligodontia: alternative technique for intermaxillary fixation.
   J Craniofac Surg. 2012;23(5):e407–e410.
6. *Ghaly GA, Bowman PA, McIntyre GT.*
   Modified wafer for orthognathic surgery in partially edentulous patients.
   Br J Oral Maxillofac Surg. 2020;58(4):486–487.
7. *Soneji BK, Esmail Z, Sharma P.*
   A modified occlusal wafer for managing partially dentate orthognathic patients - a case series.
   J Orthod. 2015;42(1):45–52.
8. *Siadat H, Arshad M, Shirani G, Alikhasi M.*
   New method for fabrication of gunning splint in orthognathic surgery for edentulous patients.
   J Dent (Tehran). 2012;9(3):262–266.

ABOUT THE AUTHORS

Univ.-Prof. Dr. Dr. Johannes Kleinheinz[1] **PD. Dr. Dr. Susanne Jung[1]** **Prof. Dr. Thomas Stamm[2]** **Dr. Claudius Middelberg[2]**

[1] Department of Cranio-Maxillofacial Surgery, University Hospital Münster, Albert-Schweitzer-Campus 1, 48149 Münster, Germany
[2] Department of Orthodontics, University Hospital Münster, Albert-Schweitzer-Campus 1, 48149 Münster, Germany

Importance of Malocclusions in Rare Diseases and Malformations Affecting the Cranio-Maxillofacial Area

Joël Ferri

Malformations and rare diseases affecting the head and neck are very frequent. It is strange to say that rare diseases are "frequent". To be objective, these pathologies are more underdiagnosed than really rare. This high prevalence in the area of the head and neck is related to the complexity of the head and neck embryology, which involves several tissues with complex edification. This situation leads to high risk of failure within the long chain of the head and neck edification.[1] These failures almost systematically cause jaw misdevelopment and, as a result, malocclusions. Contrary to popular belief, these patients (even when they have some disabilities) can have their malocclusion corrected, leading to significant improvements in diet, oral function, and social integration. The correction of these malocclusions requires an extensive team, including geneticists, orthodontists, implantologists, prosthodontists, and maxillofacial surgeons.

FIRST CASE

The first case is condylo-mandibular dysplasia. The mandibular condyle is frequently affected by malformation.[2,3,4] This particular patient was referred to our department because of significant facial malocclusion and malocclusion.

Investigations did not find any specific medical history (no rheumatoid process, trauma, TMJ ankylosis were reported).

The radiological investigations (profile cephalometry and OPT) demonstrated a missing condyle unit and the clockwise rotation of the face due to the absence of the condyle. A condyle reconstruction with a costo-chondral graft and a vertical ramus osteotomy were simultaneously performed.

Patient profile before surgery.

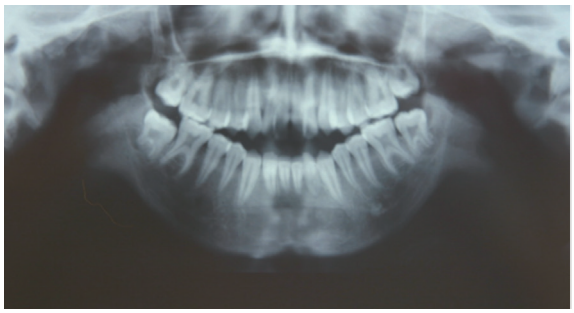

OPT: total absence of condyles.

Lateral cephalometry: significant clockwise rotation of the face.

Patient profile after surgery.

SECOND CASE

The second case is a complex oto-palato-digital syndrome. This syndrome includes malocclusion, congenital missing teeth, and orbital rim anomalies.

The patient was treated by our team and his treatment journey involved multiple stages: orthodontic treatment, orthognathic surgery, bone grafting, implant-borne prosthodontic rehabilitation.

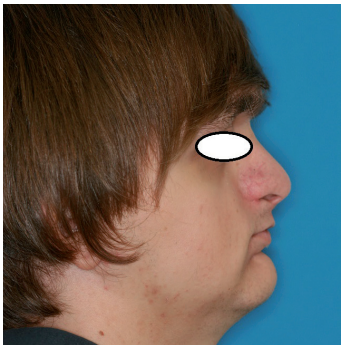

Patient profile before surgery.

Lateral cephalometry: significant craniofacial anomalies

CONCLUSION

Rare diseases that affect jaw development are very frequent. As a consequence, orthognathic surgery is frequently required if we want to normalize the occlusion. Contrary to popular belief, it possible to achieve a stable and functional occlusion for these patients.[5]

Patient occlusion.

Patient profile at the end of treatment.

Patient occlusion at the end of treatment

REFERENCES

1. *Radlanski RJ, Renz H, Zimmermann CA, Schuster FP, Voigt A, Heikinheimo K.*
   Chondral ossification centers next to dental primordia in the human mandible: A study of the prenatal development ranging between 68 to 270 mm CRL.
   Anat. 2016 Nov;208:49–57
2. *Ferri J, Carneiro JM, Lemiere E, Vereecke F, Baralle MM.*
   Severe congenital hypoplasia of the mandibular condyle-diagnosis and treatment: a report of 2 cases.
   J. Oral Maxillofac Surg. 2006 Jun;64(6):972–80
3. *Roland-Billecart T, Schlund M, Lauwers L, Nicot R, Ferri J.*
   Surgical Management of Craniomaxillofacial Features in the Otopalatodigital Spectrum Disorders.
   J Craniofac Surg. 2021 Nov–Dec 01;32(8):2823–2826.
4. *Ferri J, Schlund M, Touzet-Roumazeille S, Sciote JJ, Nicot R.*
   Temporomandibular Joint Dysplasia in Cranio-Maxillofacial Dysplasia: A Retrospective Study. Guideline Treatment Proposal.
   J Craniofac Surg. 2021 May 1;32(3):1014–1021.
5. *Promerat A, Touzet-Roumazeille S, Schlund M, Ferri J.*
   Assessing Quality of Life After Orthognathic Surgery in Disabled Patients.
   J Craniofac Surg. 2019 Nov

ABOUT THE AUTHOR

Prof. Dr. Joël Ferri
Head and Chairman of the University Hospital Lille France
Hopital R Salengro
CHRU
59037 Lille Cedex France

Headquarters

IBRA
International Bone Research Association
Hochbergerstrasse 60E
CH-4057 Basel
Phone +41 61 319 05 05
info@ibra.net
www.ibra.net

North America

IBRA North America, Inc.
Four Tower Bridge
200 Barr Harbor Drive, Suite 400
PMB# 9097
West Conshohocken, PA 19428
Phone +1 610 357 7024
info@ibra.net
www.ibra.net